

CASE REPORT

Transepidermal drug delivery: A new treatment option for areata alopecia?

MARIA CLAUDIA ALMEIDA ISSA, MARIANNA PIRES, PRISCILLA SILVEIRA,
ESTHER XAVIER DE BRITO & CRISTIANE SASAJIMA

Department of Dermatology, Hospital Universitário Antônio Pedro (HUAP), Universidade Federal Fluminense (UFF), Niterói, Brazil

Abstract

Background: Transepidermal drug delivery (TED) is a new potential method in dermatology. Permeability alterations induced by ablative fractional resurfacing have been described with the aim of increasing the delivery of different substances into the skin. **Objective:** To evaluate clinical response and side effects of TED in areata alopecia (AA) treatment using ablative fractional methods associated with acoustic pressure ultrasound (US) to deliver triamcinolone solution into the skin. **Methods and materials:** Five cases of AA underwent treatment which comprised of 3 steps: 1) Ablative fractioned RF or CO₂ laser 2) topical application of triamcinolone 3) acoustic pressure wave US. The number of sessions varied according to the clinical response, ranging from one to six sessions. **Results:** All patients had complete recovery of the area treated. Two of them treated with ablative fractional RF + triamcinolone + US had complete response after three and six sessions. The other two treated with ablative fractional CO₂ + triamcinolone + US had complete response after one session. **Conclusion:** Fractioned ablative resurfacing associated with acoustic pressure wave US is a new option to areata alopecia treatment with good clinical result and low incidence of side effects.

Key Words: alopecia, CO₂ laser, radiofrequency, transdermal administration

Introduction

The stratum corneum acts as a barrier that limits the penetration of substances through the skin (1,2). Low-frequency ultrasound (US) and, more recently, microneedle array (3,4) have been described to improve skin permeability. Application of fractional ablative methods using lasers (5,6) has been described with the aim of creating micro-channels in the epidermis to increase permeability of topically applied drugs.

Alopecia areata (AA) is the most common cause of non-scarring alopecia. It is suspected to be an autoimmune disease with a genetic predisposition. Environmental and ethnic factors seem to be involved (7). Steroids are widely used to treat AA, and intral-lesional triamcinolone is a very effective method (8).

In this study, we reported five cases of AA treated by ablative fractional resurfacing associated with acoustic pressure wave US. This procedure included

three steps: 1- Micro-channels were created in the epidermis by an ablative method—radiofrequency (RF) or CO₂ laser. 2- Triamcinolone was topically applied on the perforated skin. 3- US was applied over the steroids to push this drug into the dermis through the pre-formed micro-channels.

Methods

A prospective study was carried out to evaluate the clinical efficacy of applying steroids through transepidermal delivery by skin resurfacing associated with US in five patients with AA. To produce micro-channels in the epidermis, we used two different techniques (ablative RF and fractional CO₂ laser). The same steroid and the US were applied on the skin after both ablative techniques (RF and CO₂).

The sessions were done every 3 weeks until we could observe clinical improvement on the patch,

ranging from 1 to 6 sessions. All patients were submitted to dermatologic examination every month during the first 6 months, and were recruited to a final examination 12 months after the last session. They were advised not to use any other treatment during the study.

The degree of clinical improvement was evaluated according to a quartile scale of improvement as follows: no improvement; 1–25%, minimal improvement; 26–50%, moderate improvement; 51–75%, marked improvement; and 76–100%, excellent improvement (9). Side effects such as pain and atrophy were evaluated on a 3-point scale (0 = absent, 1 = mild, 2 = moderate, and 3 = severe). Digital photographs (Sony DSC-H9—Super Steady Shot 8.1 MP) were taken at baseline and at each follow-up visit to document clinical response.

Techniques

- RF technique

The ablative fractional RF used was unipolar RF with a roller tip. The RF roller is a 10-mm-width wheel composed of 6 cogs/disks, which has 50 pins lined on each cog's exterior rim. Six pins from each cog discharge micro-plasma causing perforation of the skin layer (holes having depth of 100–150 μm and diameter of 80–120 μm).

- CO₂ laser technique

The roller tip of the fractional CO₂ laser slides on the skin surface, producing micro-channels (pixels). It triggers a short-duration pulse of fractionated light via special beam splitter lens with fixed gaps between each 7 × 1 pixel. It produces microscopic holes having depth of 150–300 μm and diameter of 125–150 μm .

- Impact US technique

The acoustic pressure module is composed of a transducer, a sonotrode, and a distal hollow. The distal surface of the horn creates vibrational cycles (“push-pull”) on the triamcinolone. The mode of operation is based on mechanical pressure and torques by propagation of US wave (frequency: 27kHz), creating a hammering-like effect on the thin layer between the triamcinolone, the skin and the sonotrode.

Procedure

Before each session, the area to be treated was cleaned with aqueous chlorhexidine. First, ablative fractional RF or CO₂ was applied to promote fractionated ablation of the skin using the following: RF roller tip with 45 W and 4 passes (crossed); and CO₂ roller tip with 60 W, 60 mJ/pixel, spacing of 1 mm, and 2 passes (crossed). After this step, the

medication (triamcinolone acetonide, 20 mg/ml) was dropped (0.1 ml/1 cm²) on the skin surface that was pretreated with RF or CO₂. The last step was applying the US: 50 Hz (frequency of shocks) with 80% of impact intensity for 1 min in each 1 × 1 cm grid (Figure 1).

Patients

Patient 1: A 23-year-old man with an occipital patchy AA for 3 months was treated with fractional RF + triamcinolone + US—three sessions.

Patient 2: An 18-year-old woman with multiple patches of AA on the parietal area for 12 years. All the patches were treated with fractional RF + triamcinolone + US—six sessions.

Patient 3: A 47-year-old woman with an occipital patch for 1 month was treated with CO₂ laser + triamcinolone + US—one session.

Patient 4: A 38-year-old woman with a parietal patch for 3 months was treated with CO₂ laser + triamcinolone + US—one session.

Patient 5: A 35-year-old woman with AA for 12 years. Three patches were treated. One occipital patch was treated with CO₂ laser + triamcinolone + US—one session. Another occipital patch and one retro-auricular patch were treated with one session of different procedures as follows: the occipital patch was treated with CO₂ laser + triamcinolone, but without US; and the retro-auricular patch was treated with CO₂ laser isolated without triamcinolone or US. These lesions were treated with different protocols with the aim of controlling the lesions.

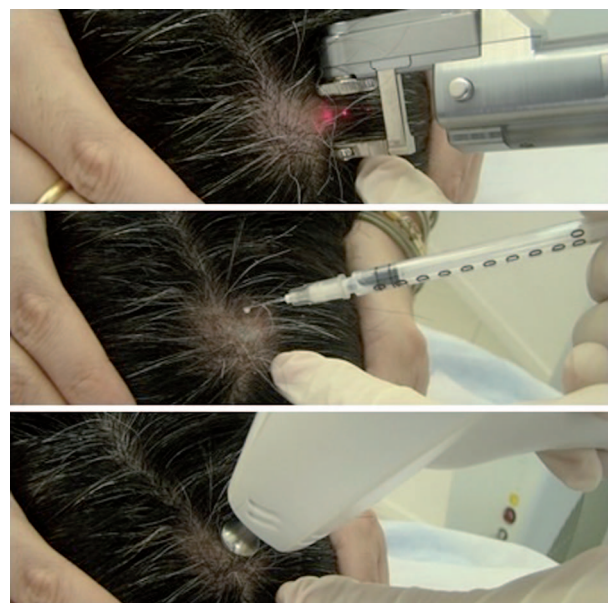


Figure 1. TED procedure with fractional ablative CO₂. First step, applying the CO₂ roller tip; second step, dropping triamcinolone acetonide on the perforated skin; third step, applying the acoustic pressure US in AA patch.

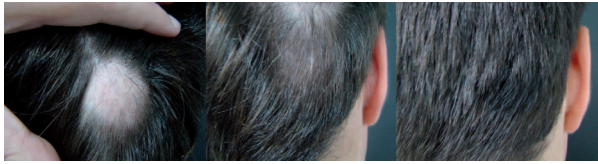

Figure 2. Gradual improvement in the patchy of AA before, after 2, and after 3 sessions of RF + triamcinolone + US, and after 12 months of treatment.

Results

In all cases, patients exhibited an excellent improvement and only one patient (patient 2) did not sustain the result after 12 months of follow-up. Patient 1 who was treated with ablative fractional RF + triamcinolone + US exhibited a complete recovery from the patch after three sessions, and the result was sustained after 12 months (Figure 2). Patient 2 was submitted to 6 sessions of ablative fractional RF + triamcinolone + US to achieve a complete response, and sustained the result for 3 months when the patient had an infectious respiratory disease. In the three patients treated with pixel CO₂ + triamcinolone + US (patients 3, 4, and 5), clinical improvement could be observed in the first month just after one session of treatment—the result sustained after 12 months (Figure 3). On the other hand, as patient 5 had two other patches treated with different procedures, she exhibited different clinical responses. The complete clinical response could only be observed in the patch treated with the complete procedure (CO₂ + triamcinolone + US). We could observe a minimal clinical improvement in the occipital patch after fractional ablation (CO₂ laser isolated) + triamcinolone without US (Figure 4a1 and a2), and any response was observed on the retro-auricular patch

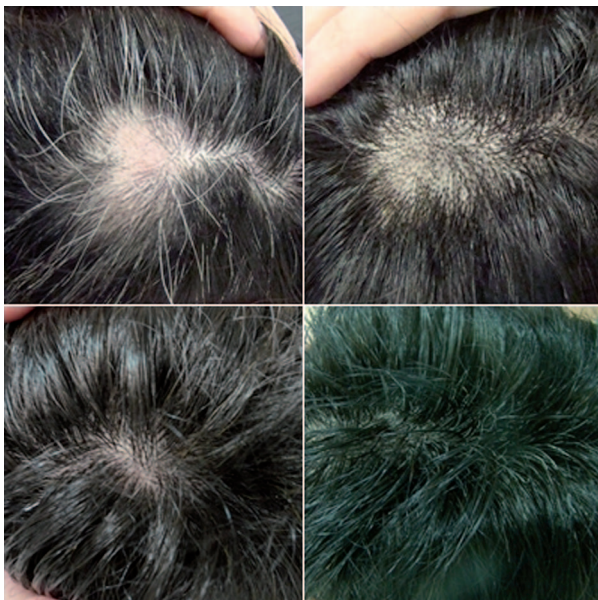


Figure 3. Before, 3 weeks, 3 months, and 12 months after treatment, one session of CO₂ + triamcinolone + US.

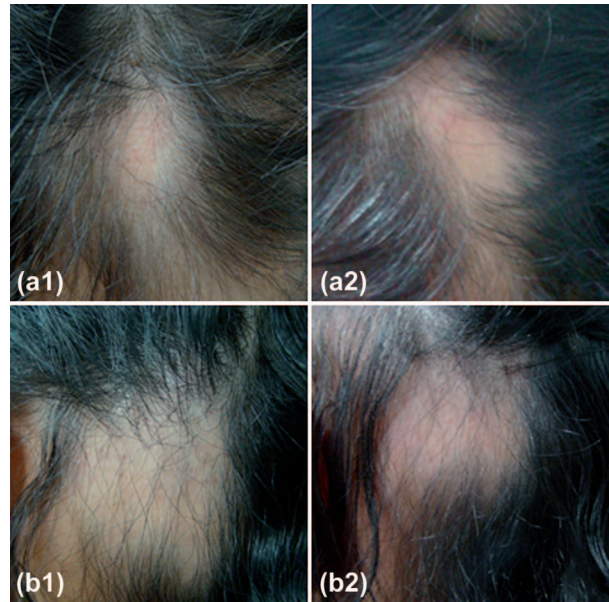


Figure 4. a1, a2: Occipital area: before and 3 months after CO₂ laser + triamcinolone without US. 4 b1, 4 b2: Retro-auricular area: before and 3 months after CO₂ laser isolated without triamcinolone or US.

treated with fractional ablation (CO₂ laser) isolated (Figure 4b1 and b2).

None of the patients had atrophy in the treated area. They reported mild burning sensation during the procedure.

Discussion

A number of treatments can induce hair growth in AA, and have been reported in literature, such as topical, systemic, and intralesional corticosteroid injections (8); topical immunotherapy (10); phototherapy (11); minoxidil (12); and dithranol (13). The use of fractionated resurfacing to create micro-channels in the epidermis to improve drug delivery into skin is a new concept of treatment called transepidermal drug delivery (TED) and have been reported in literature. Gómez et al. (5) reported that Erbium laser ablation of the stratum corneum enhances transepidermal delivery of 5-fluorouracil. Another article published by Haerdersdal et al. (6) evaluated drug delivery by CO₂ laser ablative fractional resurfacing using methyl 5-aminolevulinate. A new study on Photodynamic therapy (PDT) after fractional ablative RF associated with impact US was reported in literature with good clinical results in actinic keratosis treatment—even with methyl aminolevulinate incubation time reduced to 1 h (14). In 2012, the use of ablative fractional RF and acoustic pressure US associated with retinoic acid 0.05% cream was described as a safe and effective method for alba-type Striae distensae (SD) treatment (15). More recently, we reported some cases of transepidermal triamcinolone acetate delivery using the

same technique in hypertrophic scars treatment as a new possibility of treatment with high efficacy and low side effects (16).

In this study, we used two different technologies to promote ablative fractional skin resurfacing—ablative fractional RF and ablative fractional CO₂—both of them being associated with an acoustic pressure wave (impact US) which acted as a hammer to push the triamcinolone into the epidermis through the micro-channels pre-formed by RF and CO₂ with the aim of increasing triamcinolone acetonide permeability in AA patches.

It seems that with this new technique, triamcinolone is applied more homogeneously on the skin compared with that by needle injection, facilitating the treatment. Our control lesions showed the importance of the complete procedure, using an ablative method + triamcinolone + impact US.

Conclusion

TED using ablative fractional RF and CO₂ in association with high-pressure acoustic wave US to deliver triamcinolone acetonide provided an excellent clinical result within few sessions with low side effects in AA treatment. This new method of TED was effective and avoided the pain and skin atrophy caused by needle in intradermal injection of triamcinolone.

Declaration of interest: The authors report no declarations of interest. The authors alone are responsible for the content and writing of the paper.

References

- Curdy C, Kalia YN, Guy RH. Non-invasive assessment of the effects of iontophoresis on human skin in-vivo. *J Pharm Pharmacol* 2001;53:769–777.
- Mori K, Hasegawa T, Sato S, Sugibayashi K. Effect of electric field on the enhanced skin permeation of drugs by electroporation. *J Control Release* 2003;90:171–179.
- McAllister DV, Allen MG, Prausnitz MR. Microfabricated microneedles for gene and drug delivery. *Annu Rev Biomed Eng* 2000;2:289–313.
- Henry S, McAllister DV, Allen MG, Prausnitz MR. Microfabricated microneedles: a novel approach to transdermal drug delivery. *J Pharm Sci* 1998;87:922–925.
- Gómez C, Costela A, García-Moreno I, Llanes F, Tejió JM, Blanco D. Laser treatments on skin enhancing and controlling transdermal delivery of 5-fluorouracil. *Lasers Surg Med* 2008;40:1–12.
- Haerdersdal M, Sakamoto FH, Farinelli WA, Doukas AG, Tam J, Anderson RR. Fractional CO₂ laser-assisted drug delivery. *Lasers Surg Med* 2010;42:113–122.
- Al-Mutairi N, Eldin ON. Clinical profile and impact on quality of life: seven years experience with patients of alopecia areata. *Indian J Dermatol Venereol Leprol* 2011; 77:489–493.
- Chang KH, Rojhirunsakool S, Goldberg LJ. Treatment of severe alopecia areata with intralesional steroid injections. *J Drugs Dermatol* 2009;8:909–912.
- Walgrave SE, Ortiz AE, MacFalls MT, Elkeeb L, Truitt AK, Tournas JA, et al. Evaluation of a novel fractional resurfacing device for treatment of acne scarring. *Lasers Surg Med* 2009;41:122–127.
- Wiseman MC, Shapiro J, MacDonald N, Lui H. Predictive model for immunotherapy of alopecia areata with diphenylprone. *Arch Dermatol* 2001;137:1063–1068.
- Taylor CR, Hawk JL. PUVA treatment of alopecia areata partialis, totalis and universalis: audit of 10 years' experience at St John's Institute of Dermatology. *Br J Dermatol* 1995;133:914–918.
- Fenton DA, Wilkinson JD. Topical minoxidil in the treatment of alopecia areata. *Br Med J (Clin Res Ed)* 1983;287: 1015–1017.
- Fiedler-Weiss VC, Buys CM. Evaluation of anthralin in the treatment of alopecia areata. *Arch Dermatol* 1987;123: 1491–1493.
- Kassuga LEBP, Issa MCA, Chevrant NS. Aplicação transepidermica de medicamento associado a terapia fotodinâmica no tratamento de ceratoses actínicas. *Surg Cosmet Dermatol* 2012;4:89–92.
- Issa, MCA, Kassuga LEBP, Chevrant NS, do Nascimento Barbosa L, Luiz RR, Pantaleão L, et al. Transepidermal retinoic acid delivery using ablative fractional radiofrequency associated with acoustic pressure ultrasound for stretch marks treatment. *Lasers Surg Med* 2013;45:81–88.
- Issa MCA, Kassuga LEBP, Chevrant NS, Pires MT. Topical delivery of triamcinolone via skin pretreated with ablative radiofrequency: a new method in hypertrophic scar treatment. *Int J Dermatol* 2013;52:367–370.