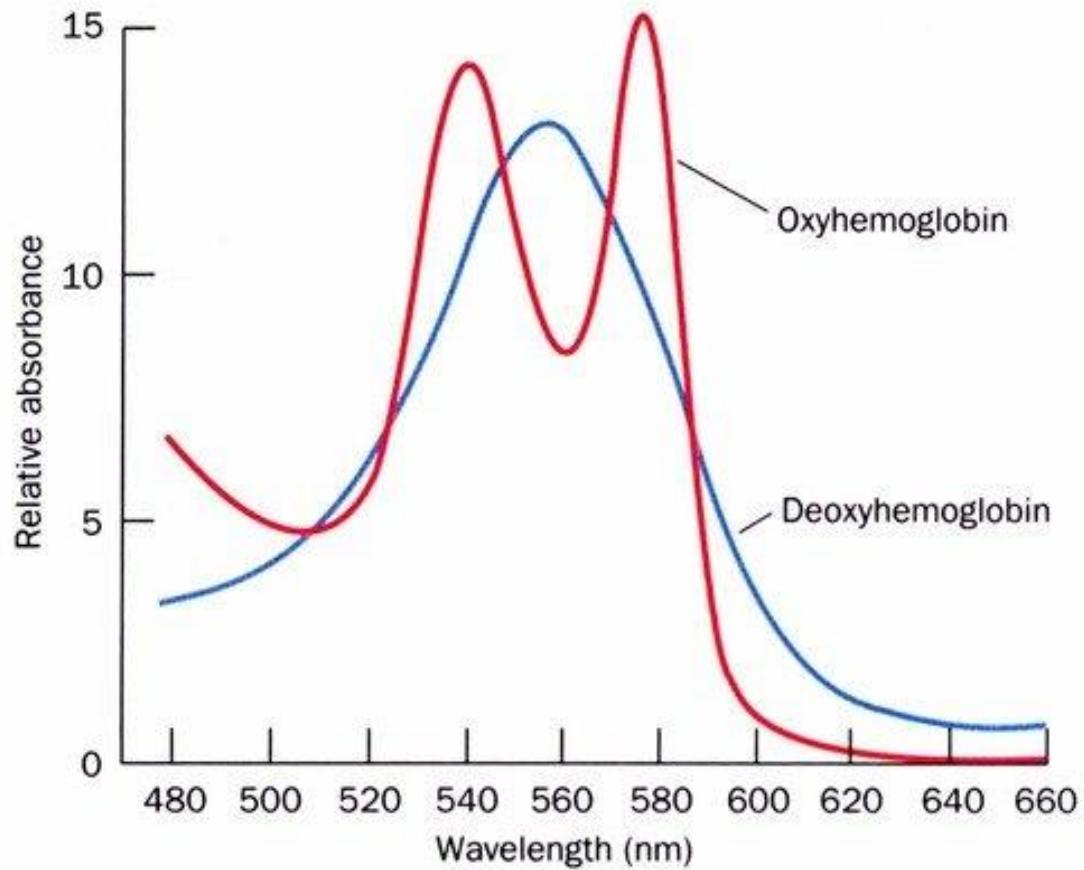

Indications

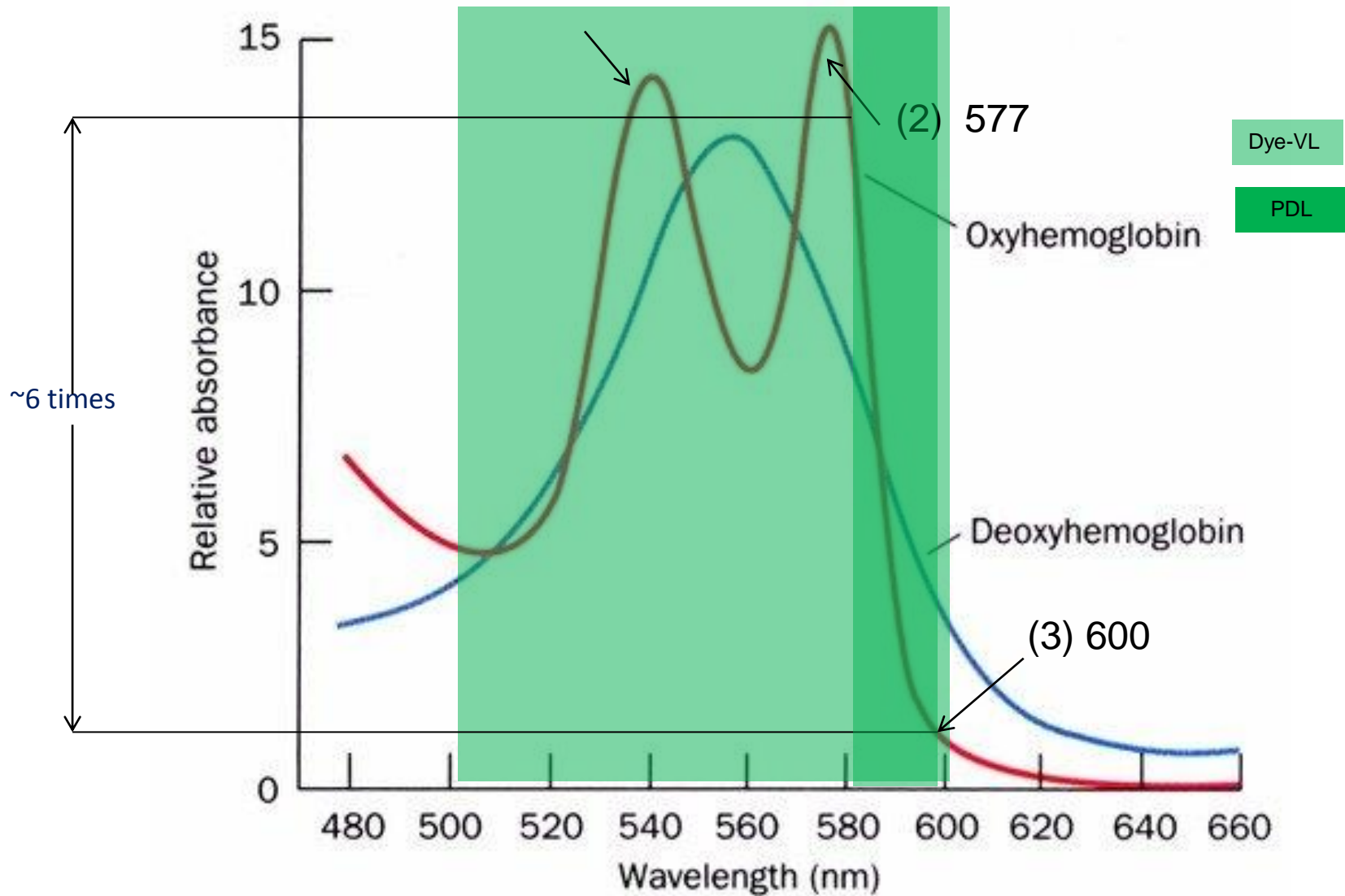
- Vascular Lesions

- ✓ Port wine stains
- ✓ Facial telangiectasia
- ✓ Rosacea & Hemangioma
- ✓ Poikiloderma of Civatte
- ✓ Photodamaged/Photaged skin

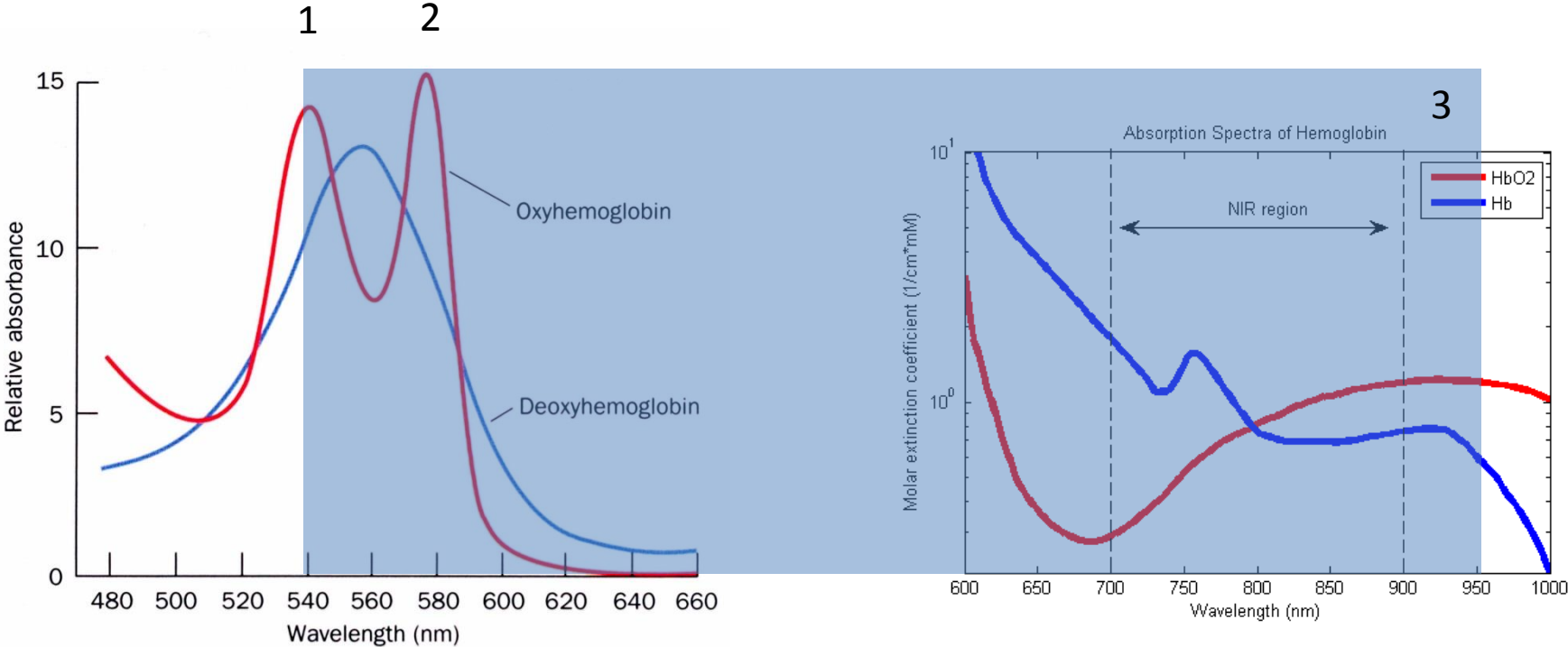
- Pigmented Lesions

Benign pigmented epidermal lesions (hyperpigmentation, freckles, lentigines)

(1) 542



540-950nm

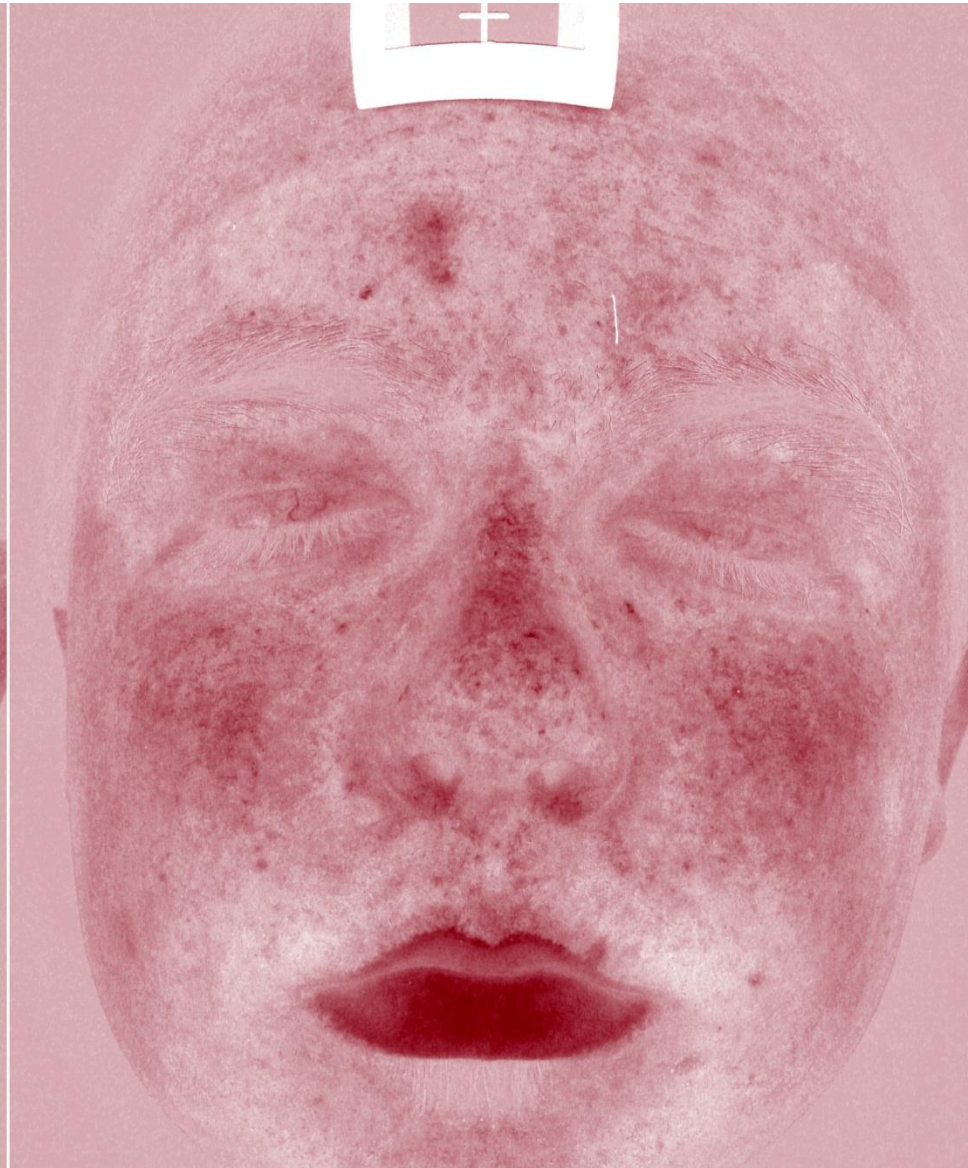
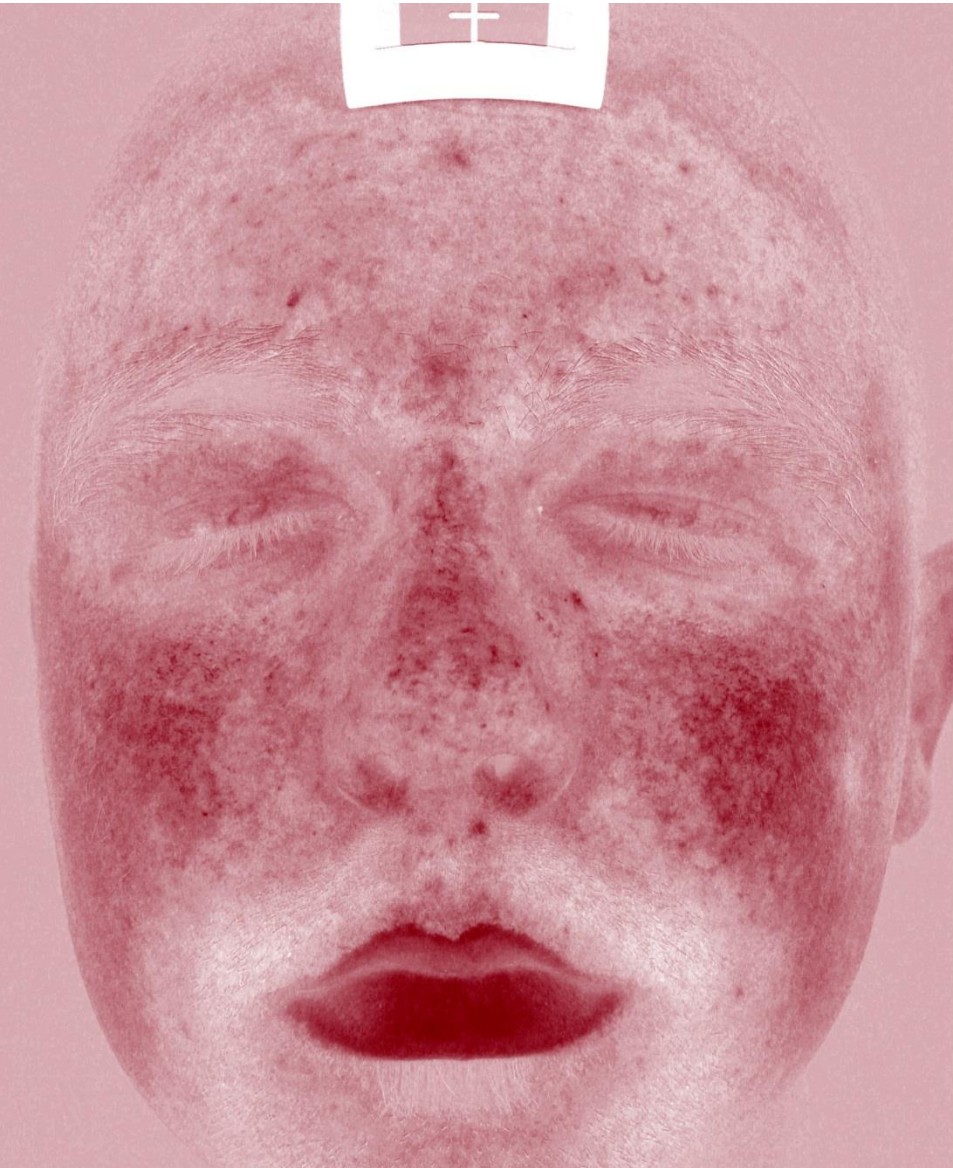

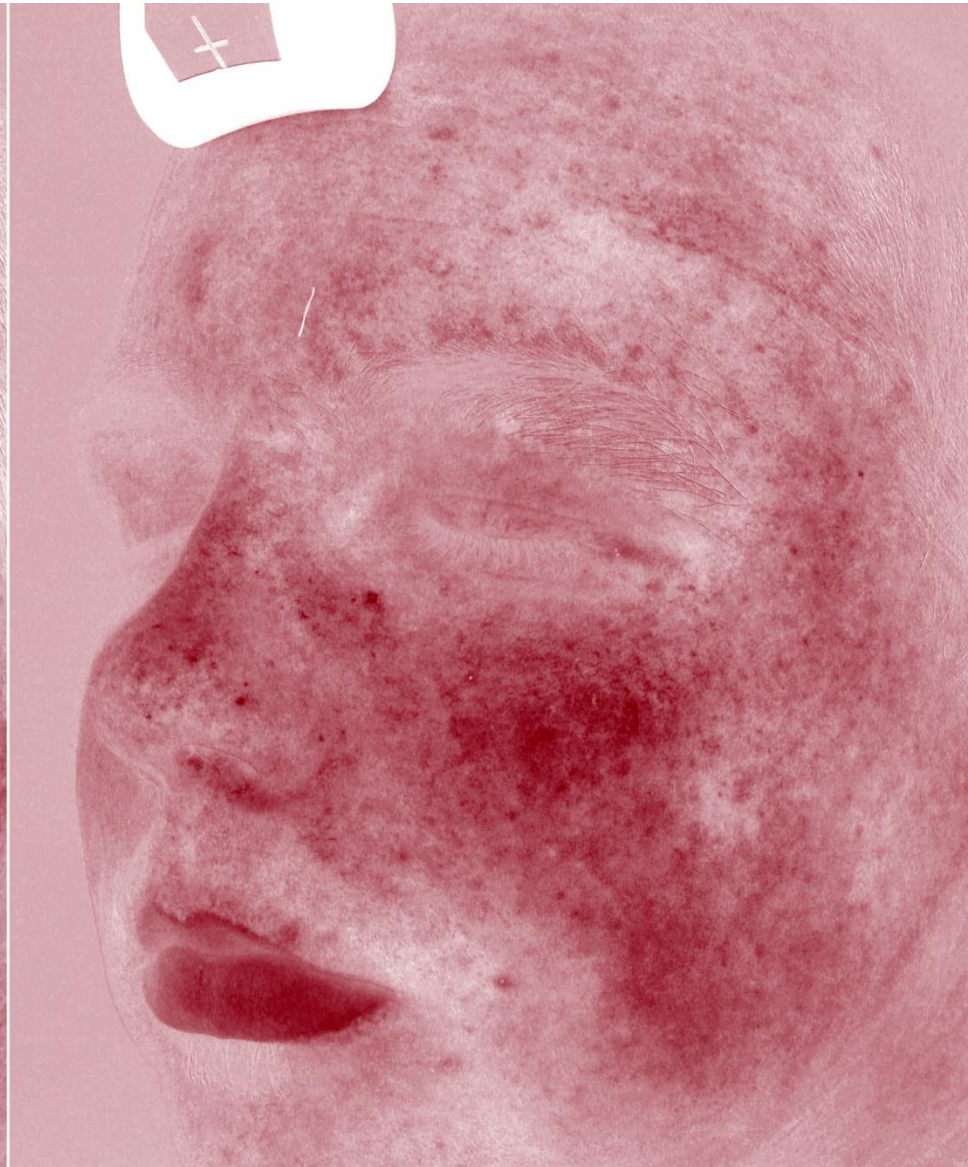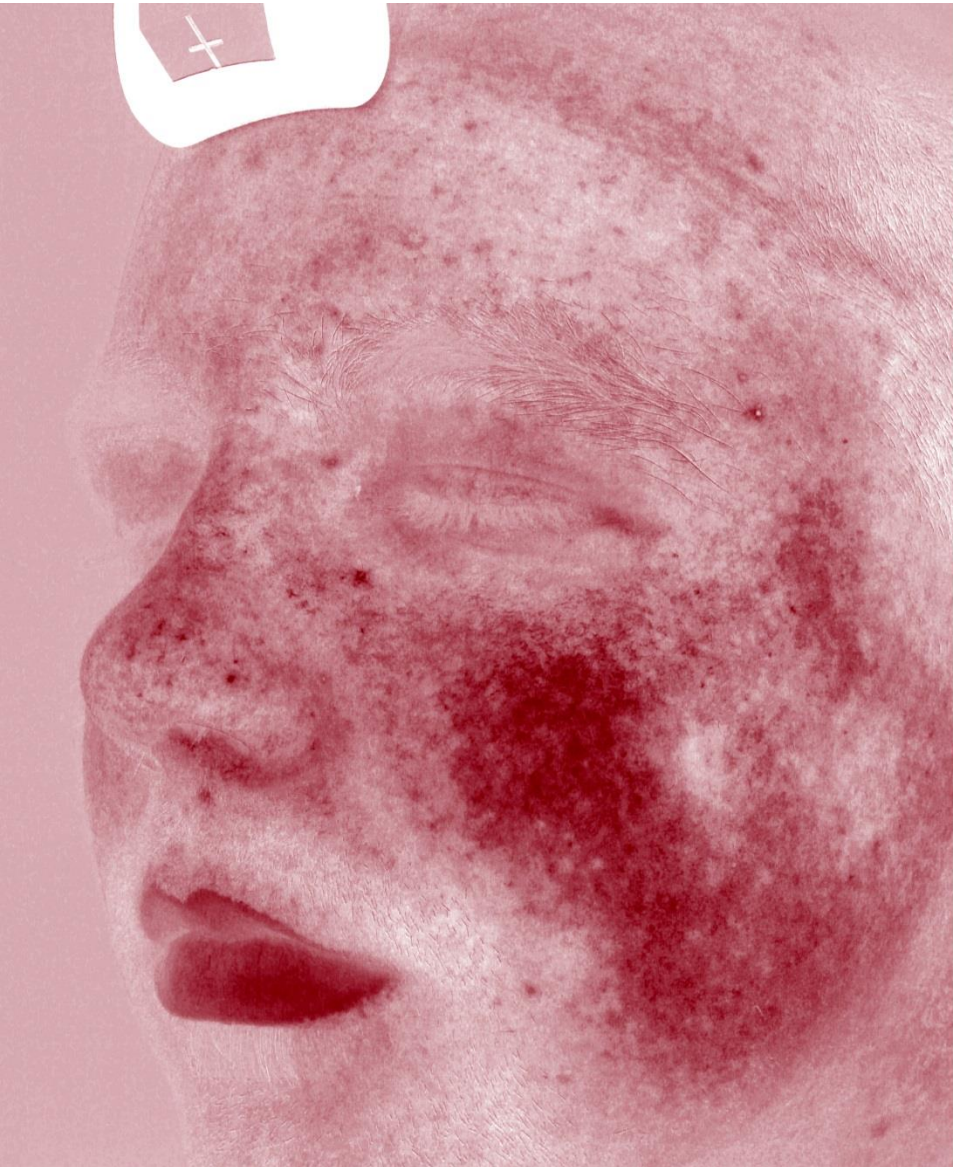By Dr. Dinko Kaliterna

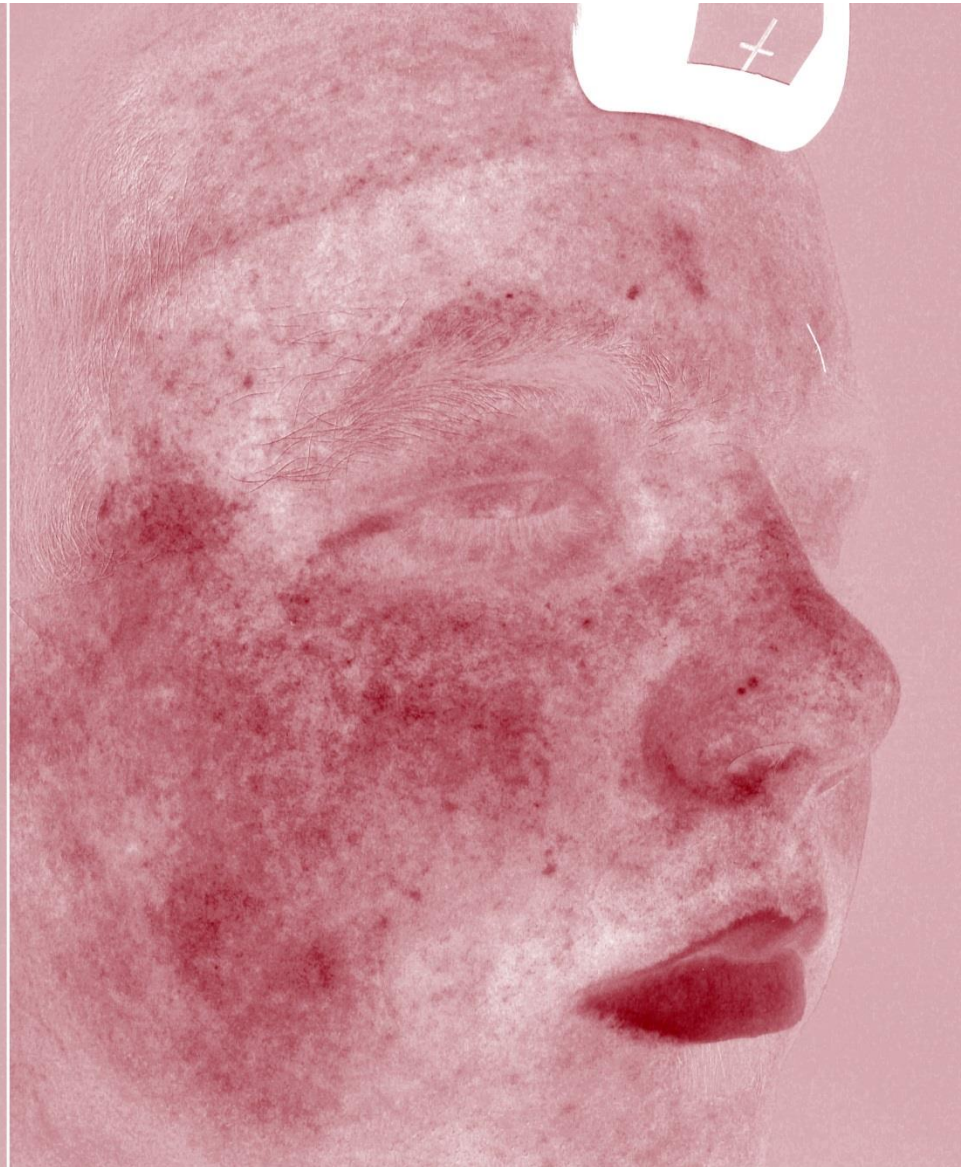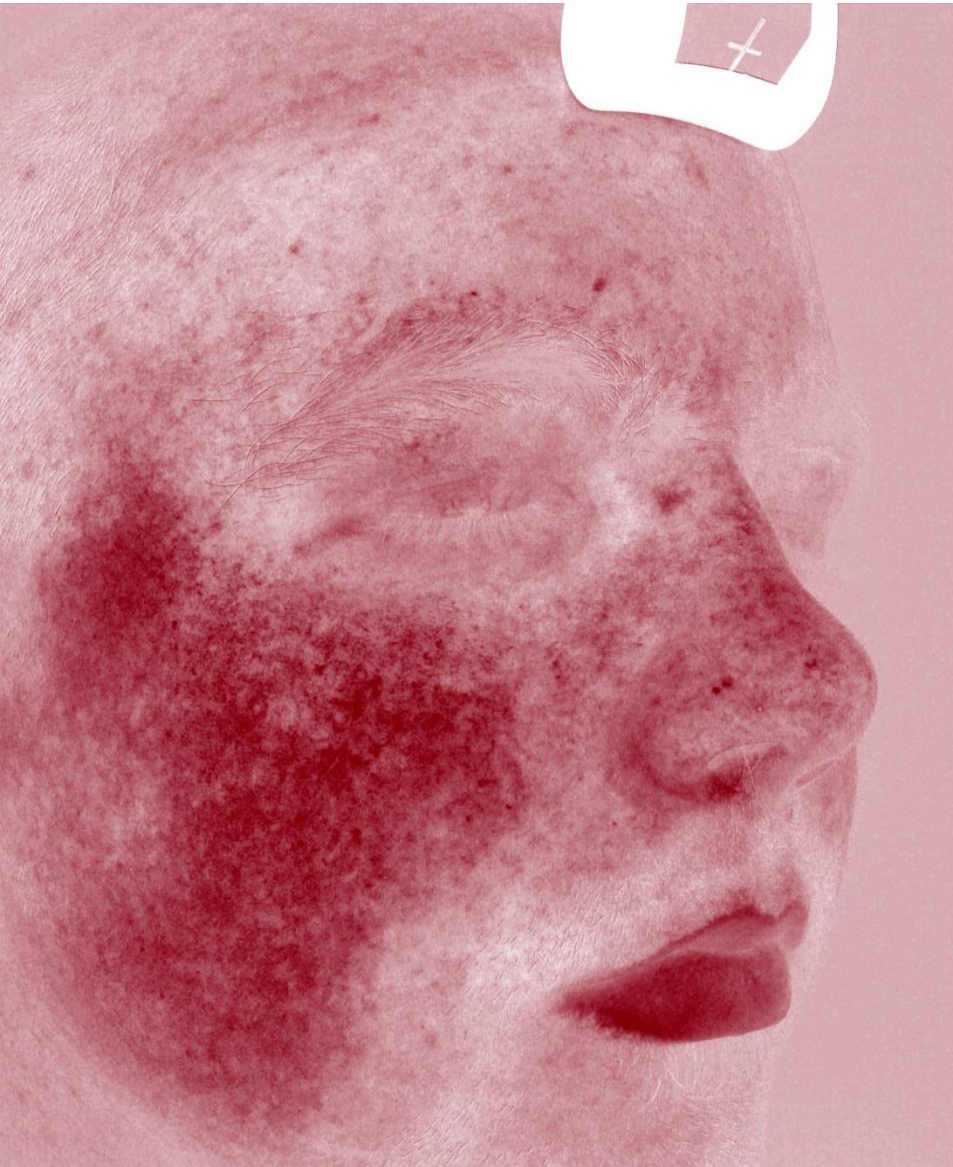B&A Pictures Collection

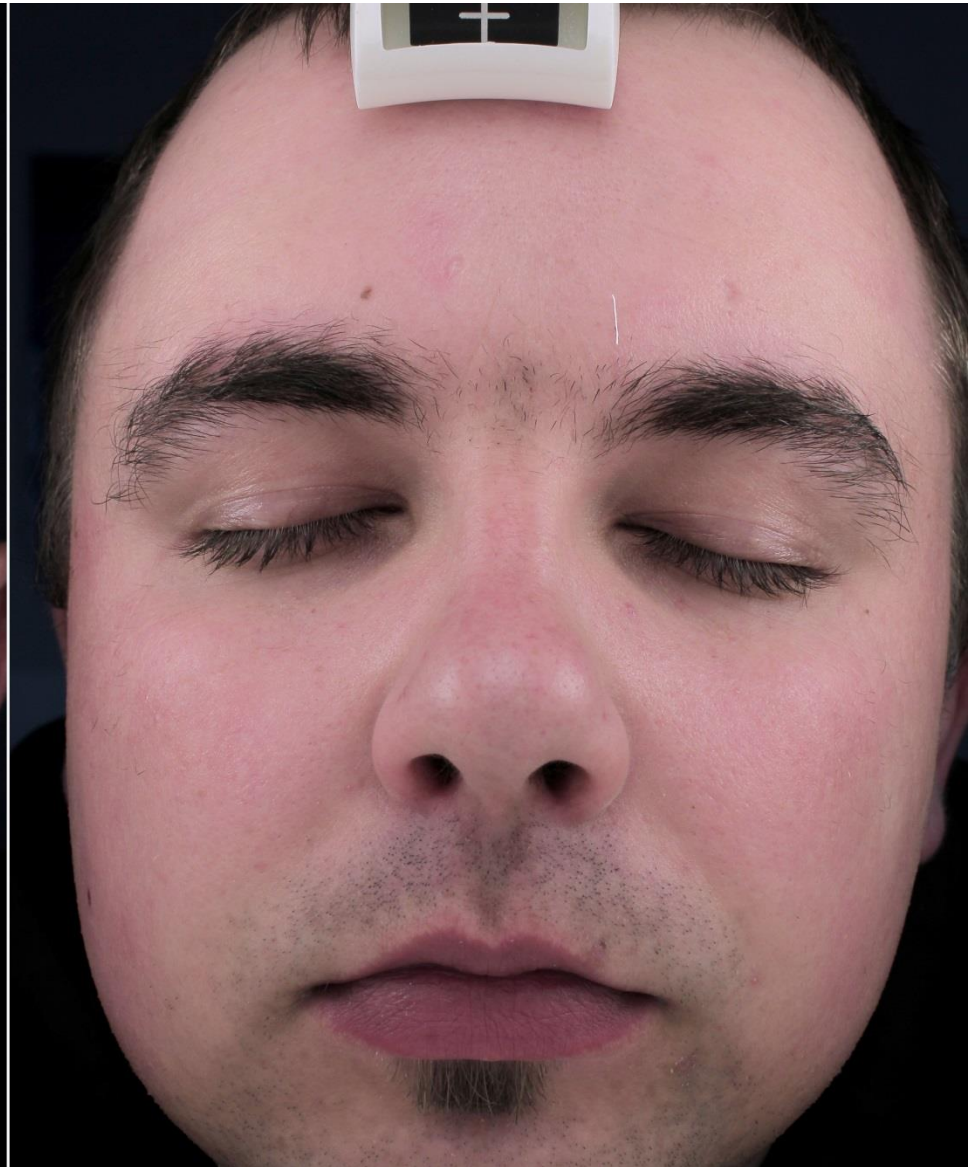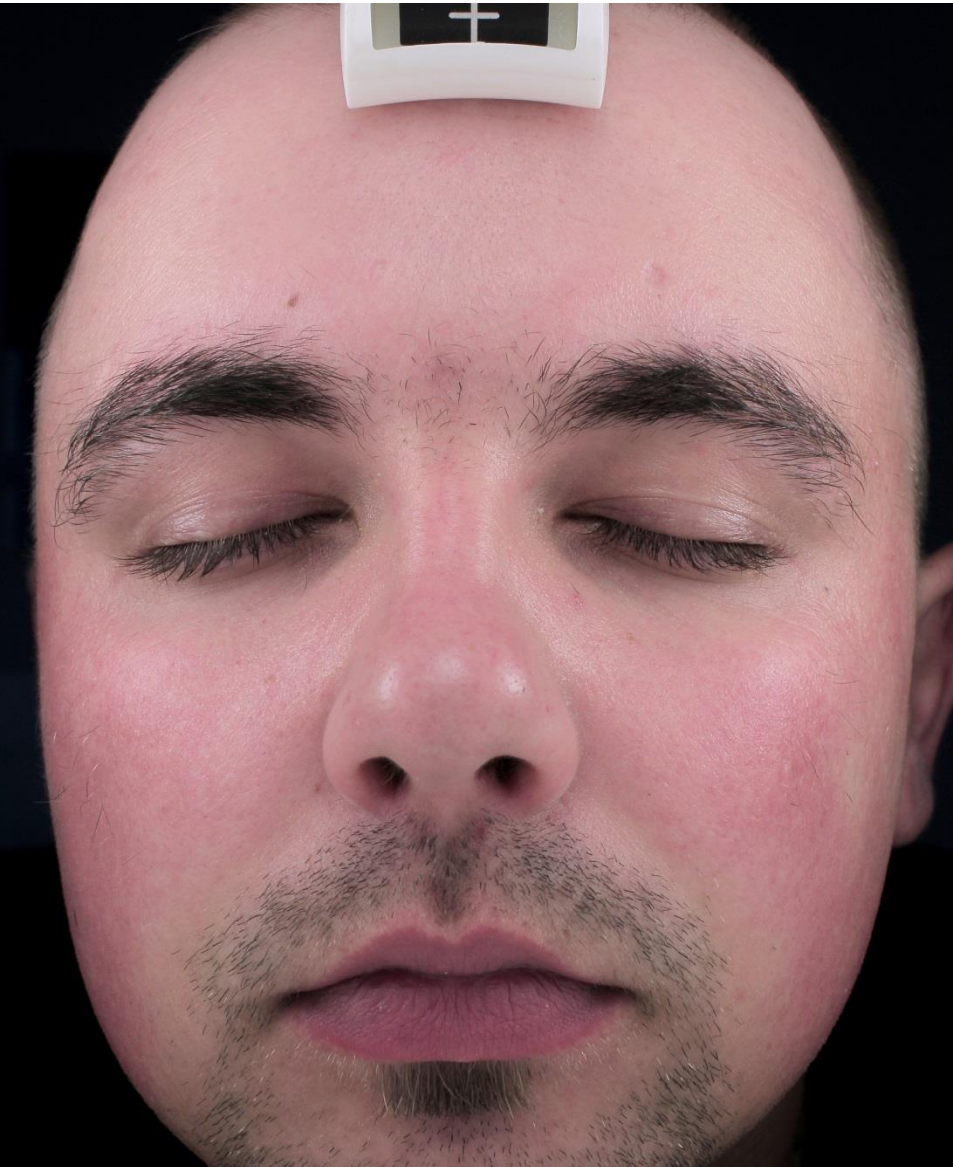2013

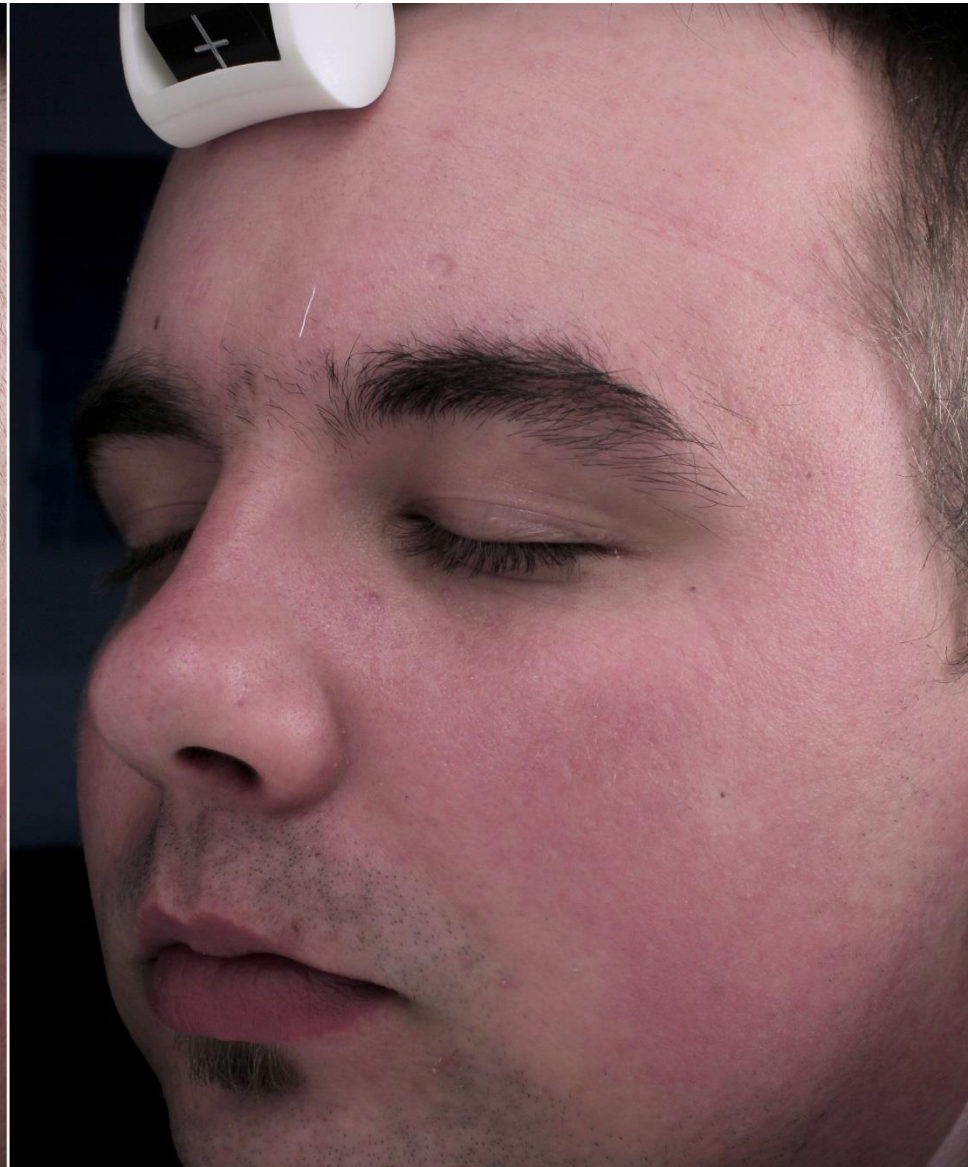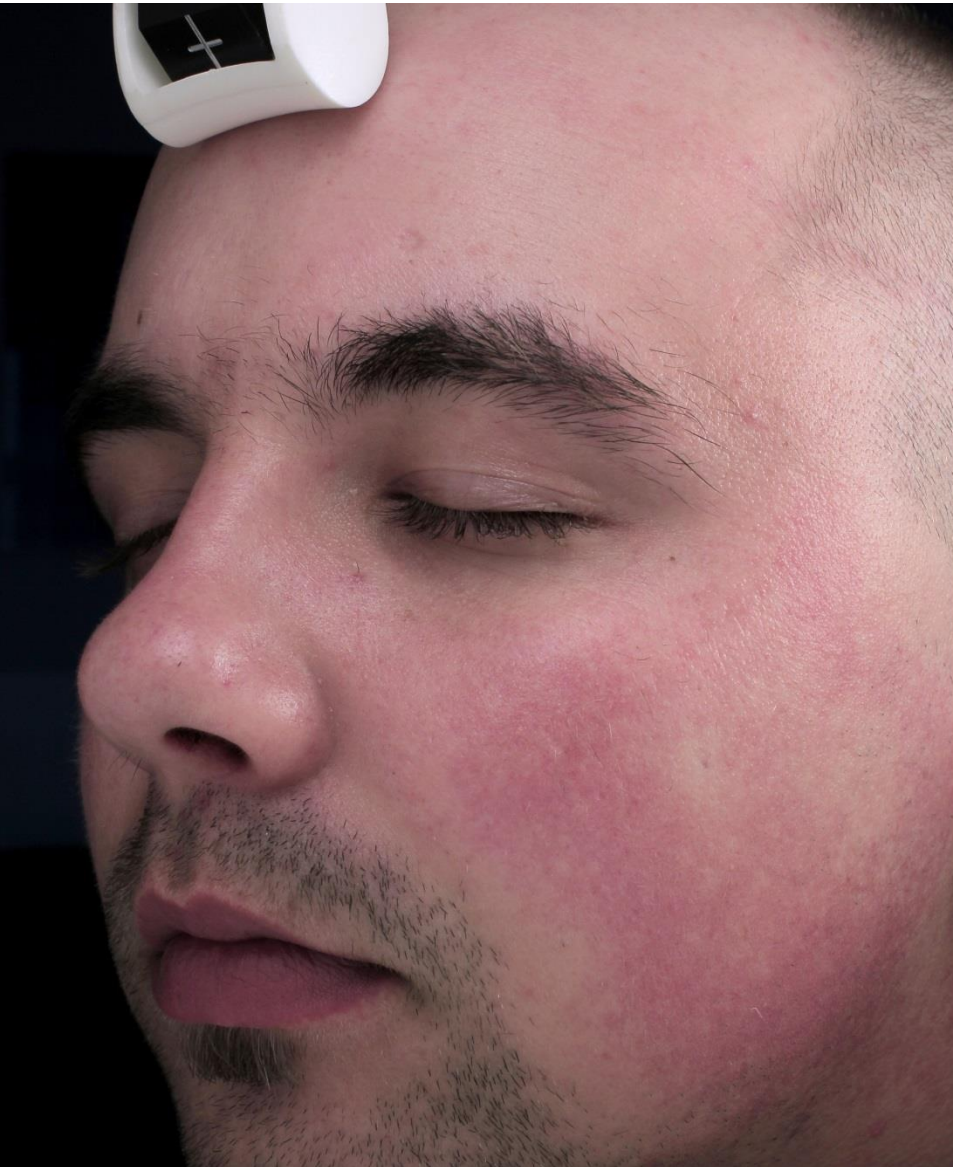Rosacea – Dye -12J , 13J, 14J

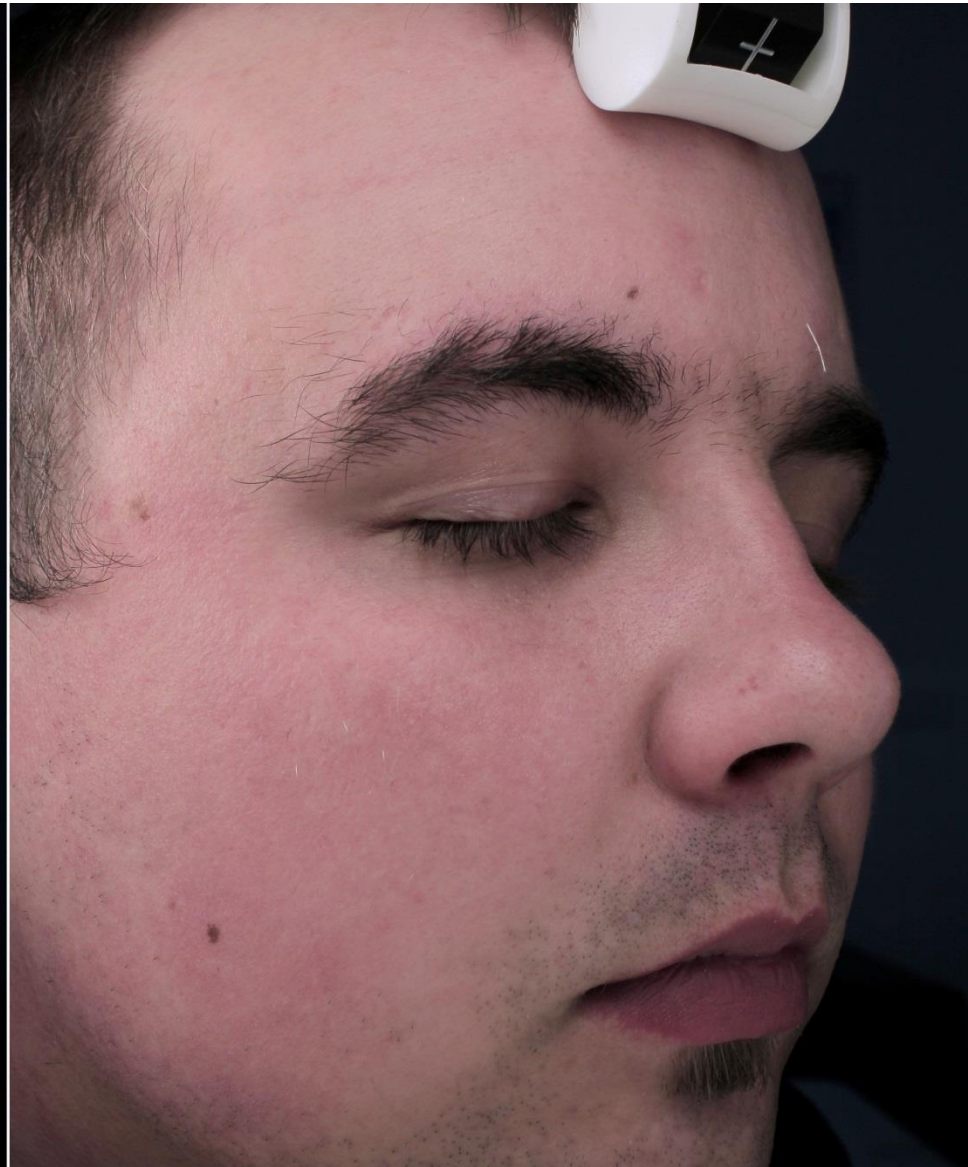
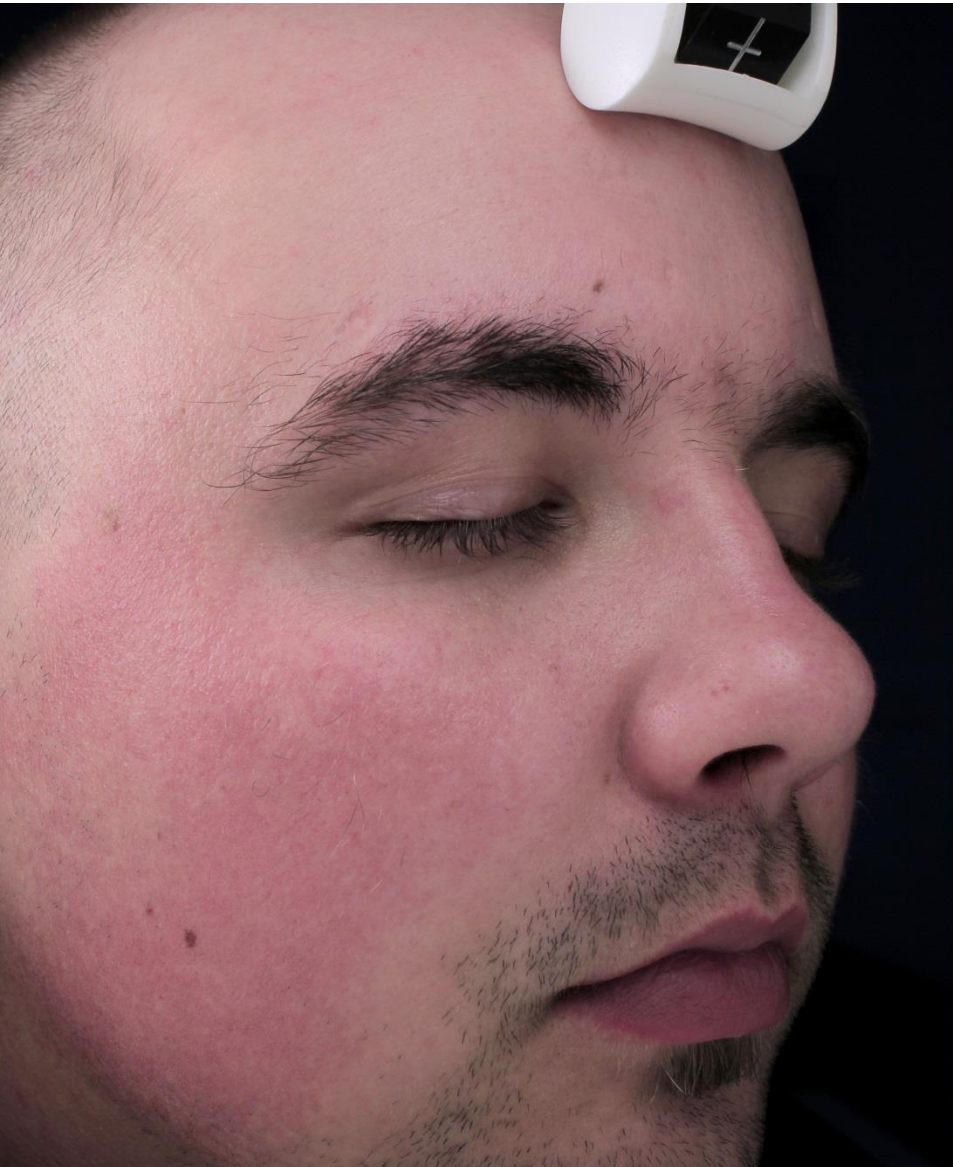






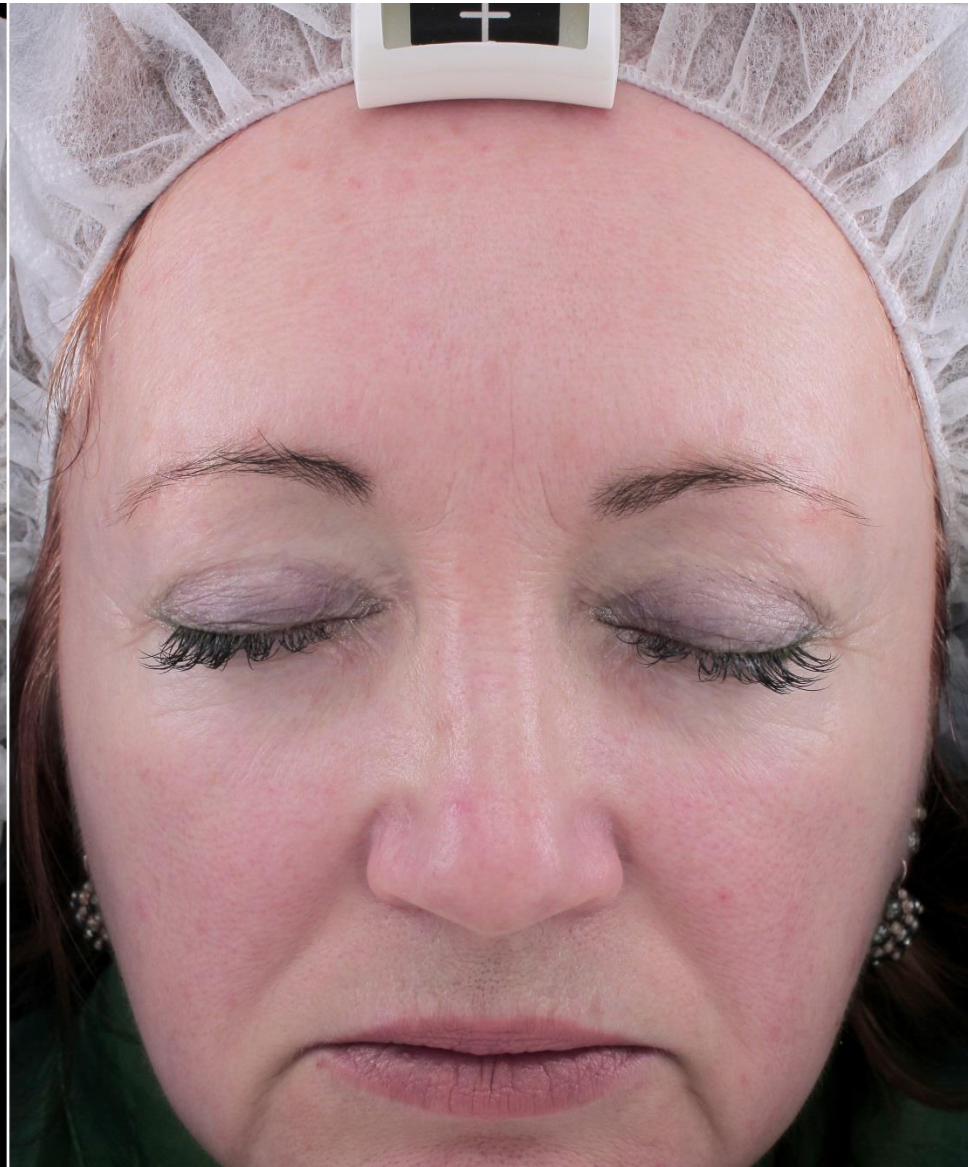
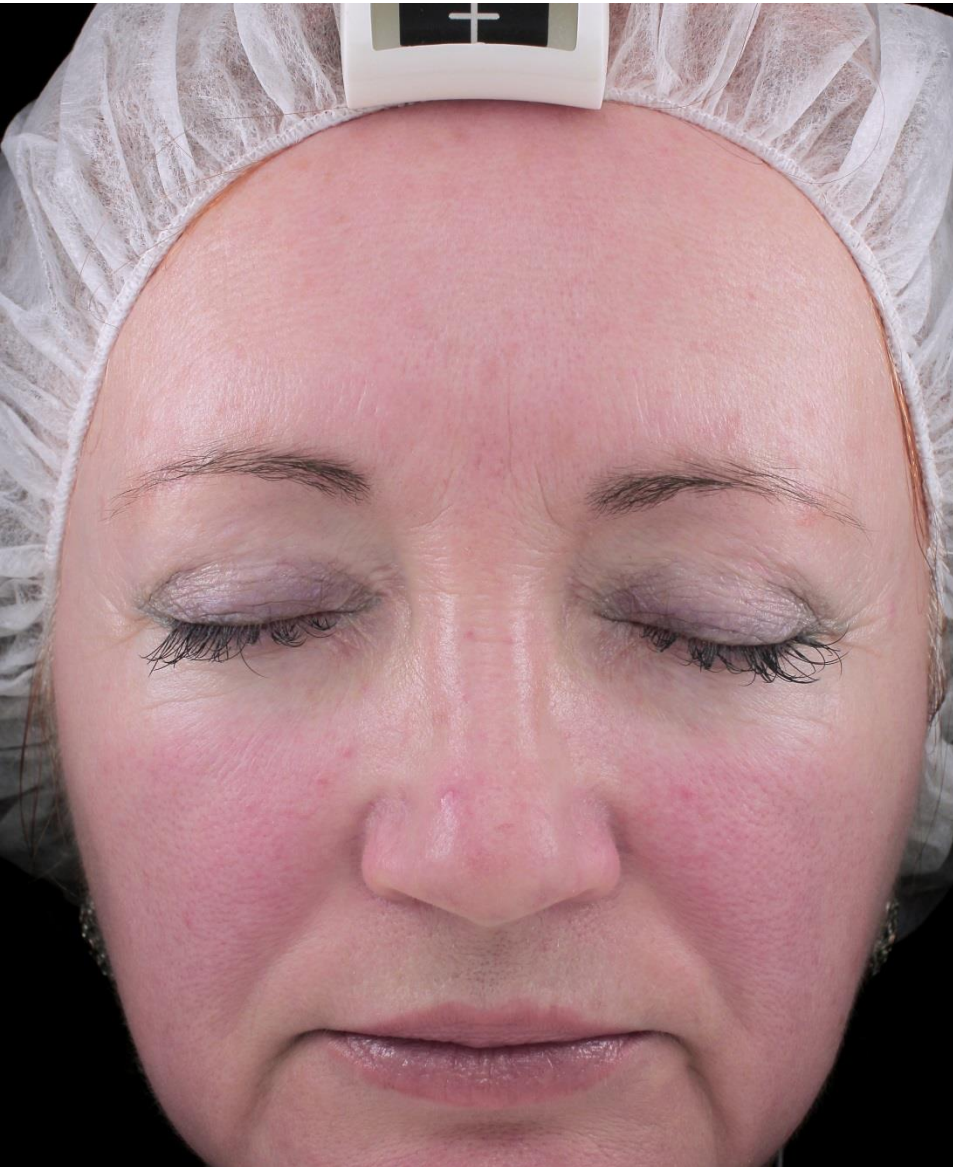


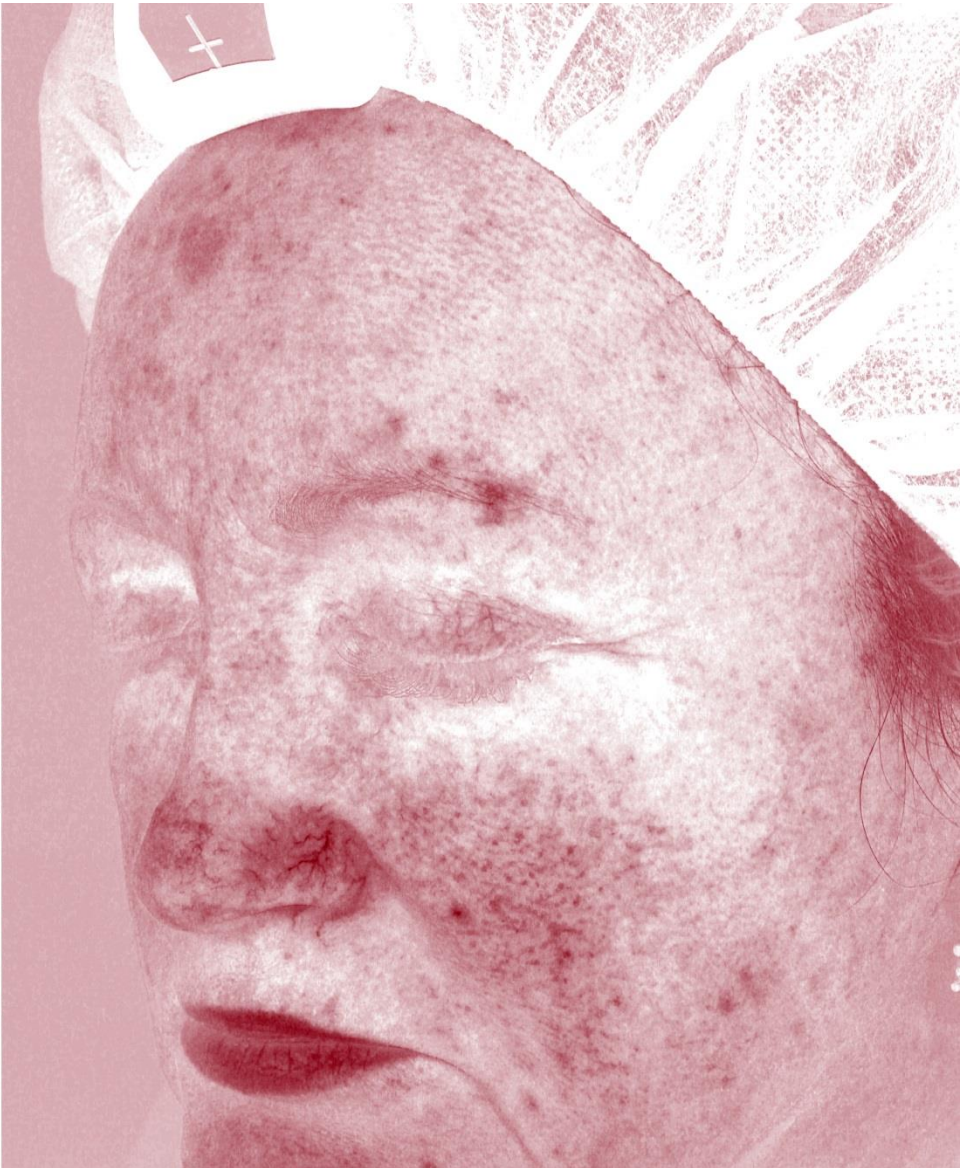
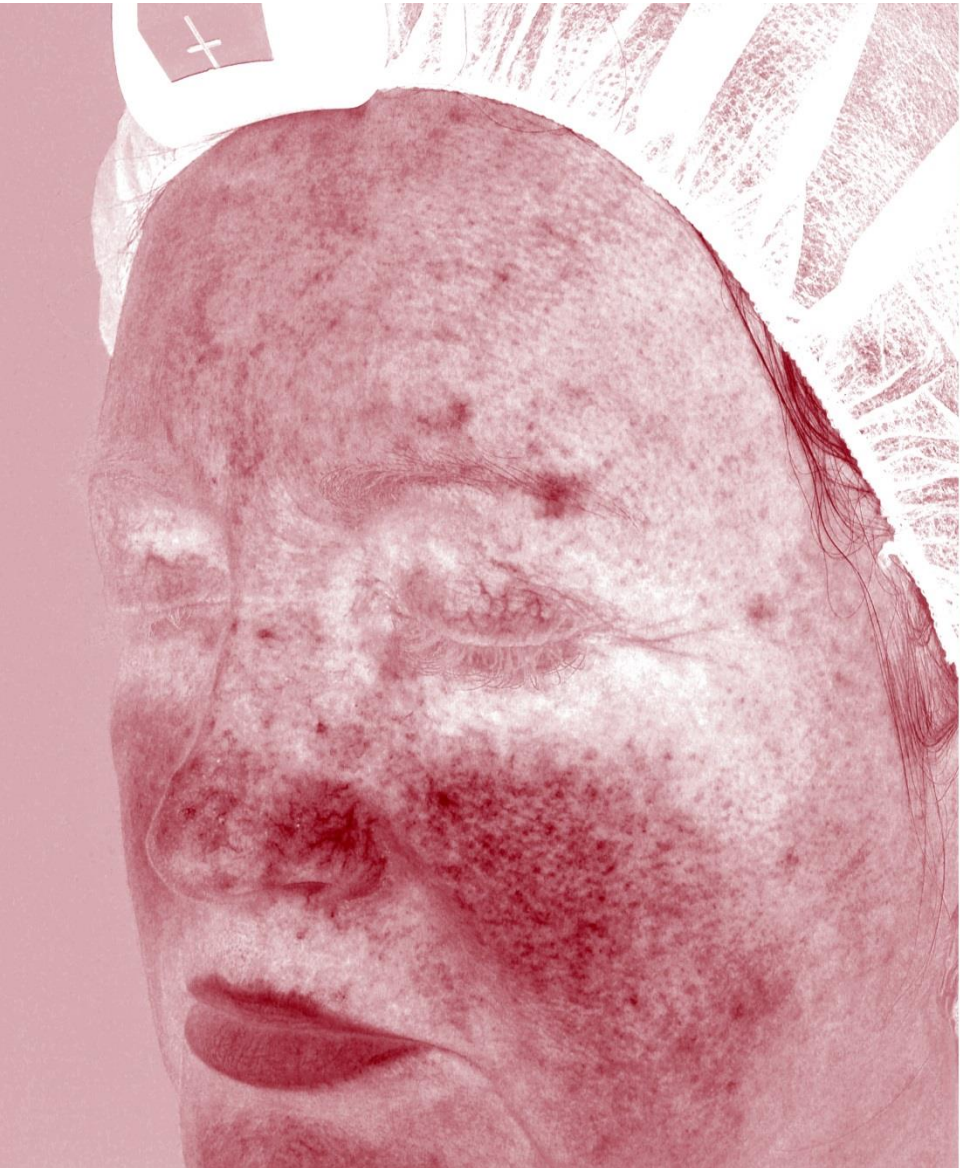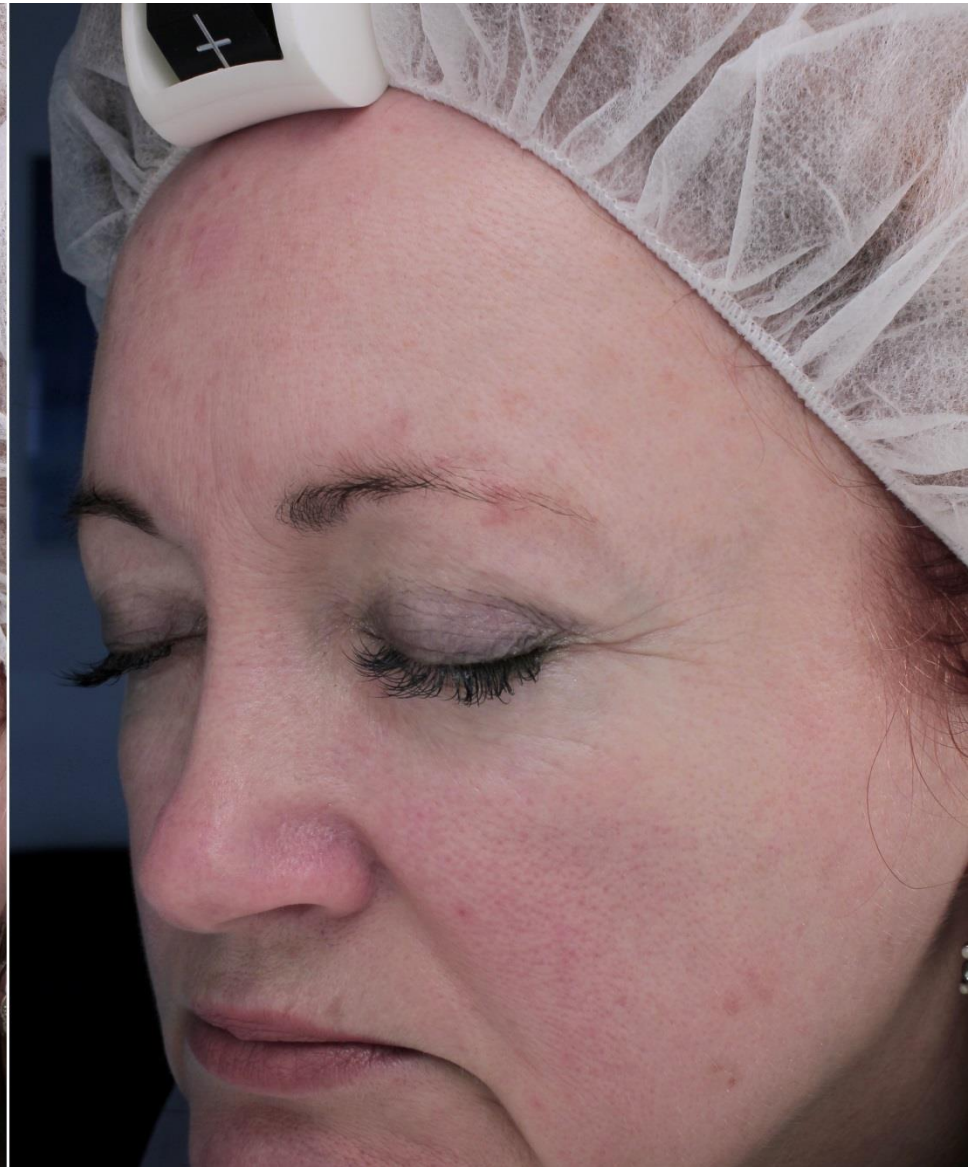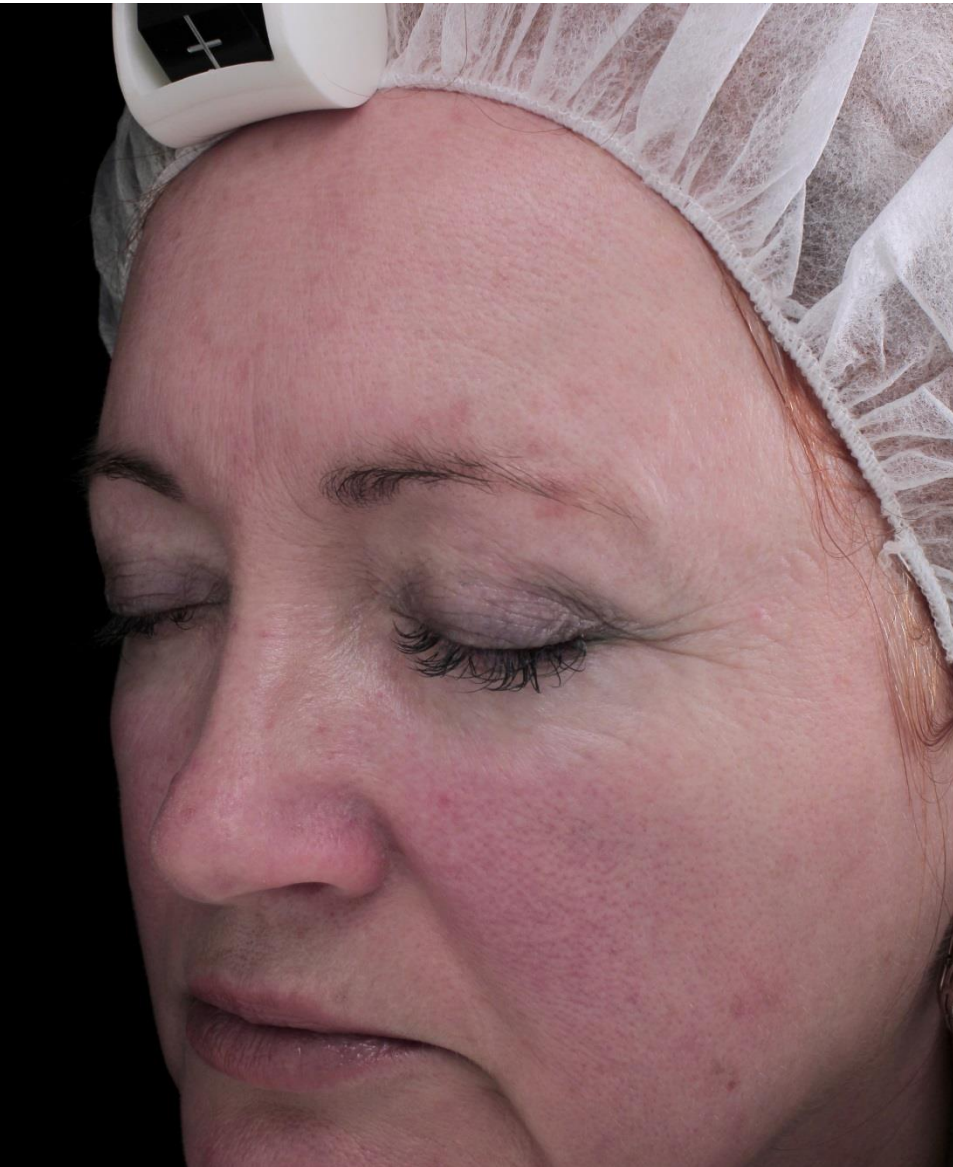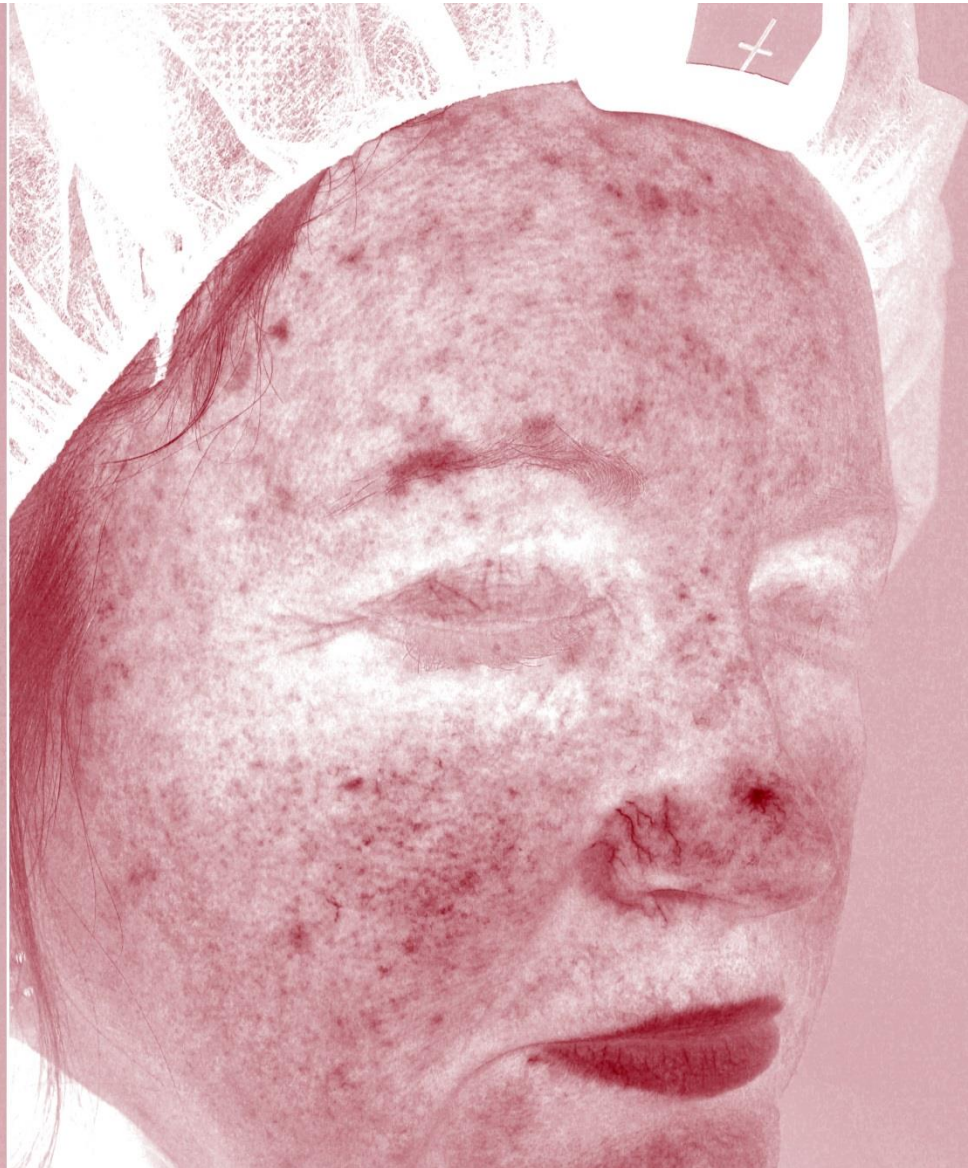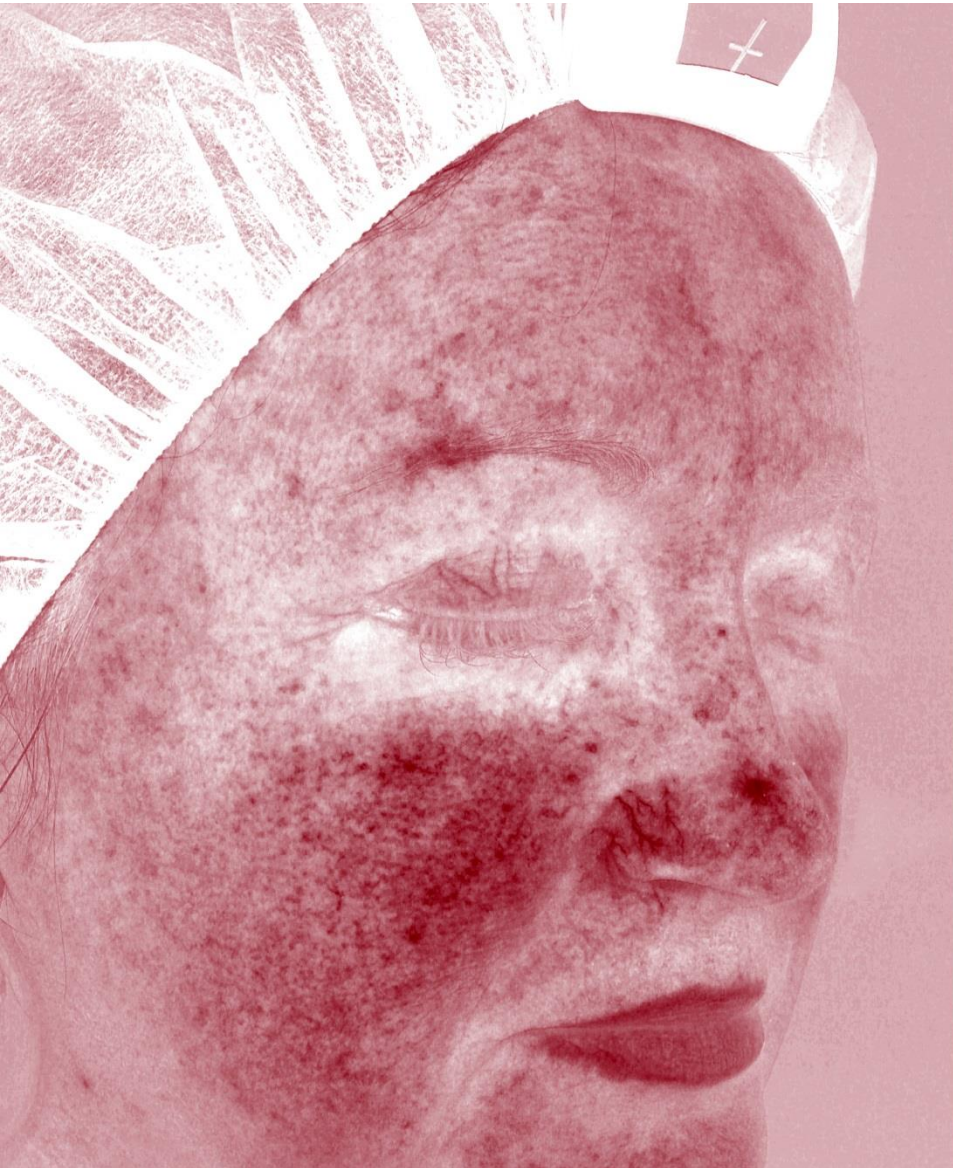Rosacea

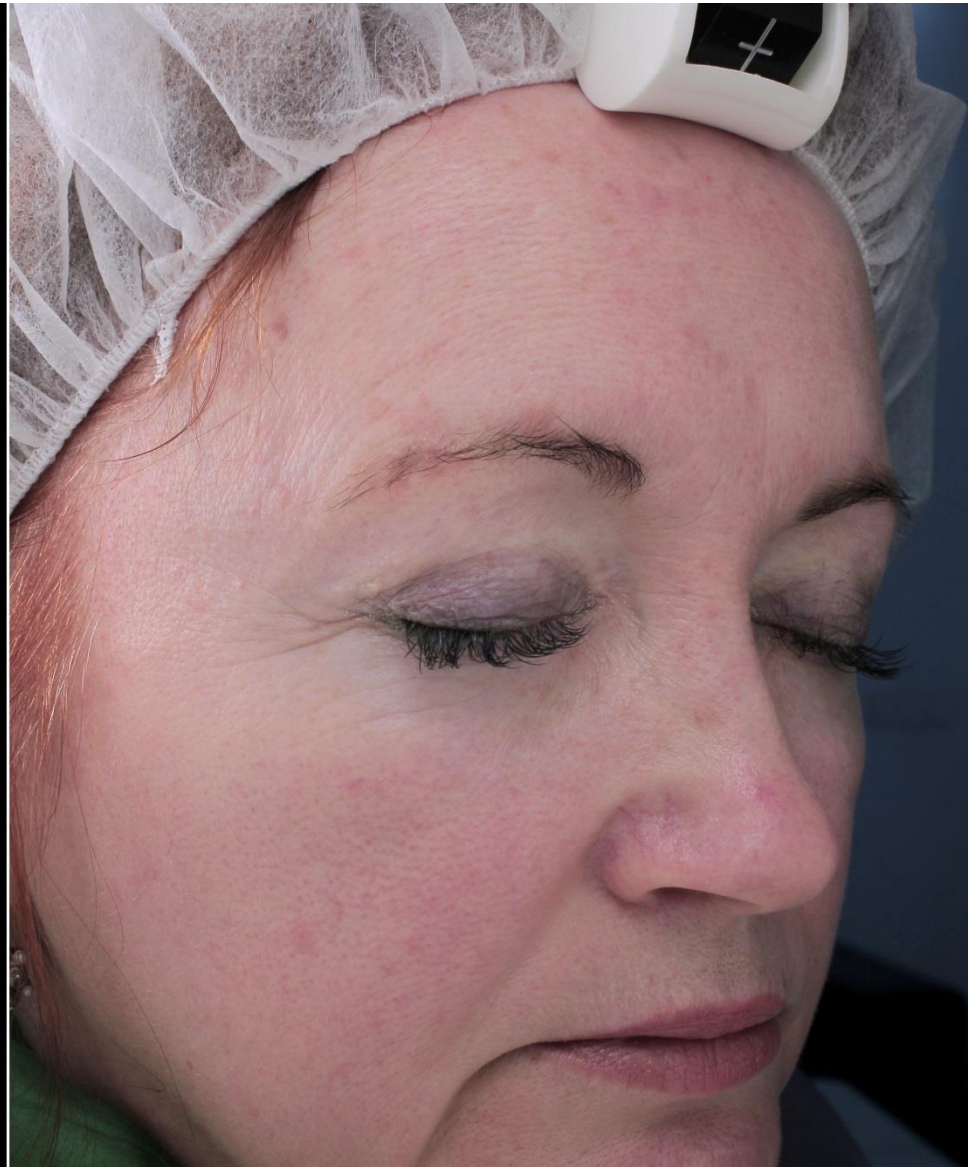
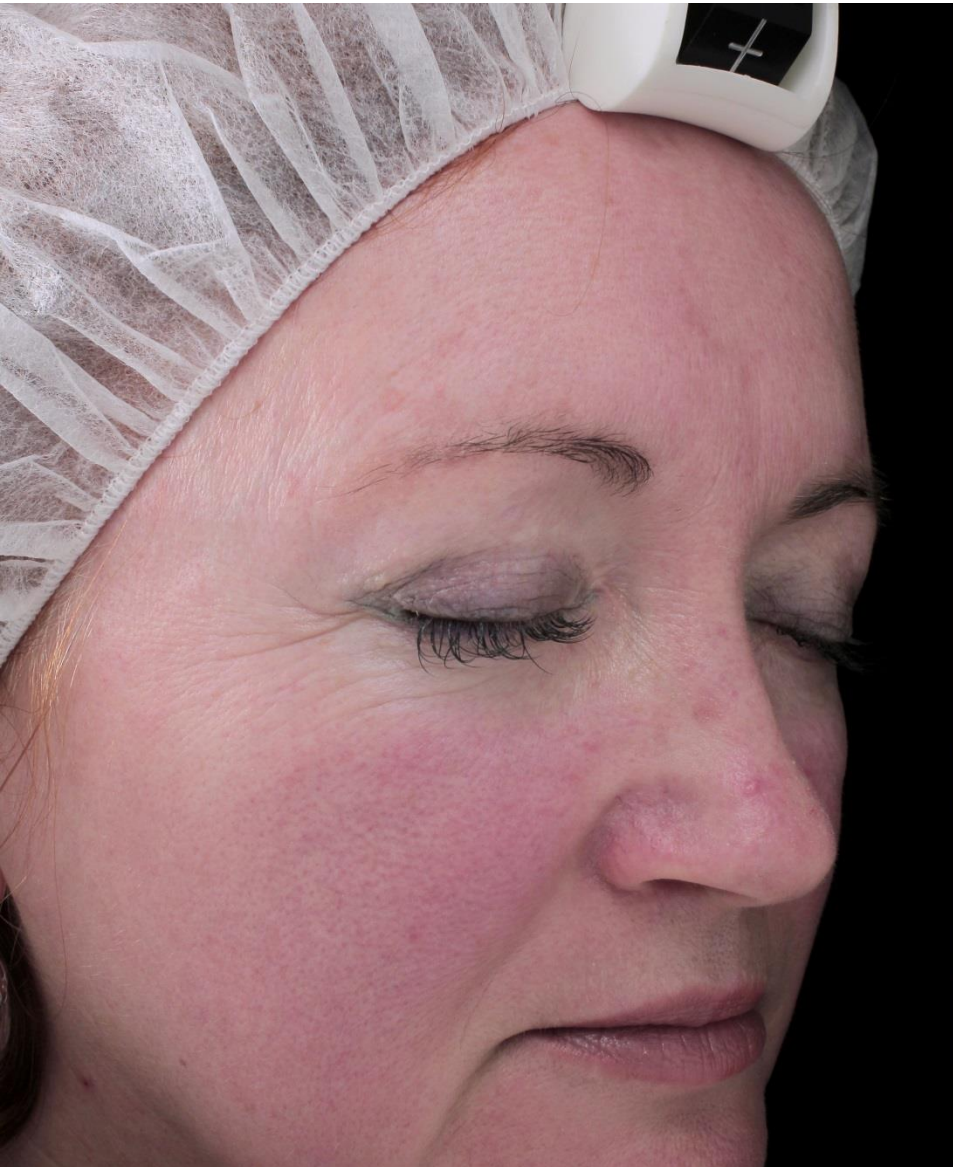


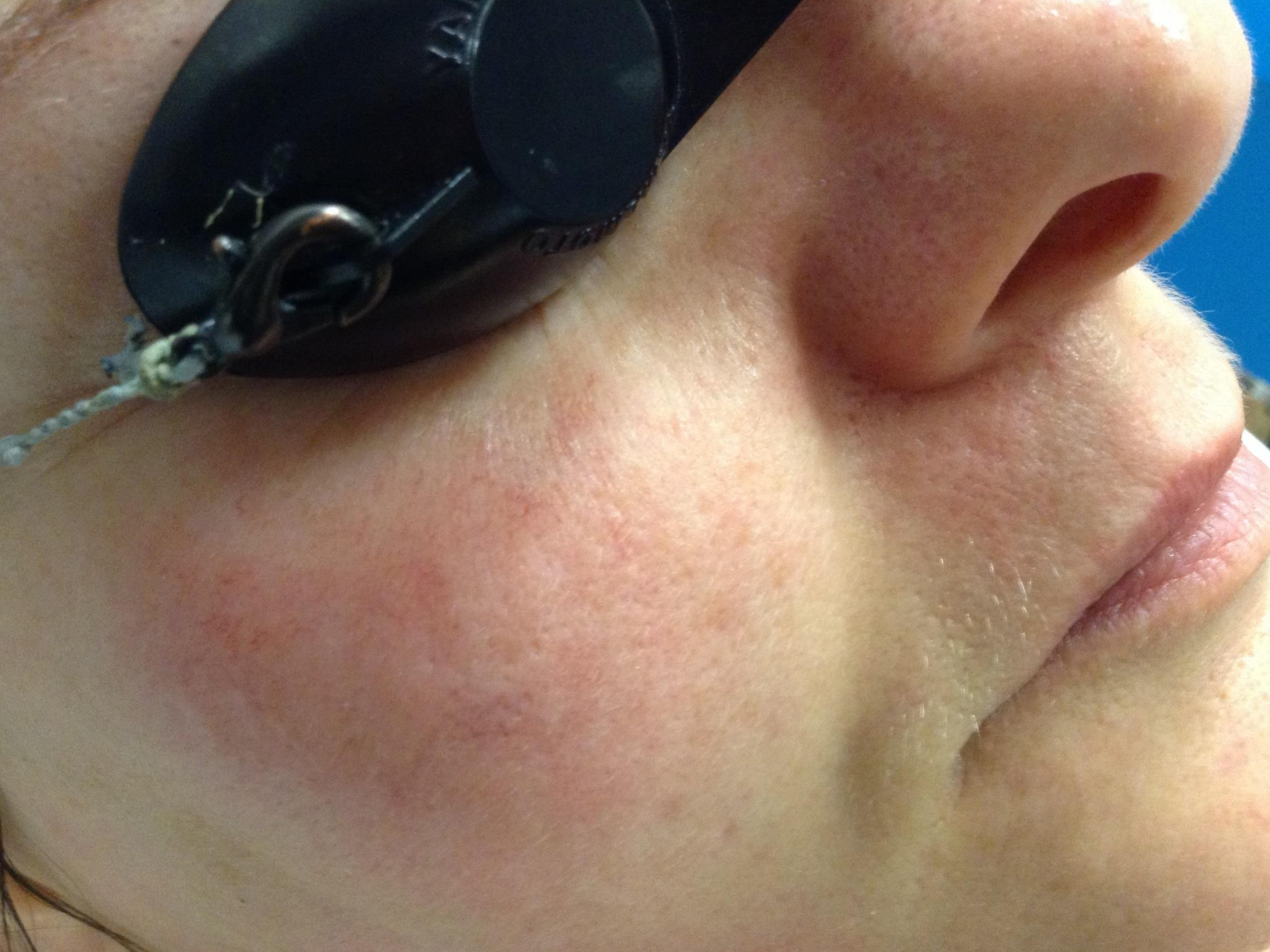


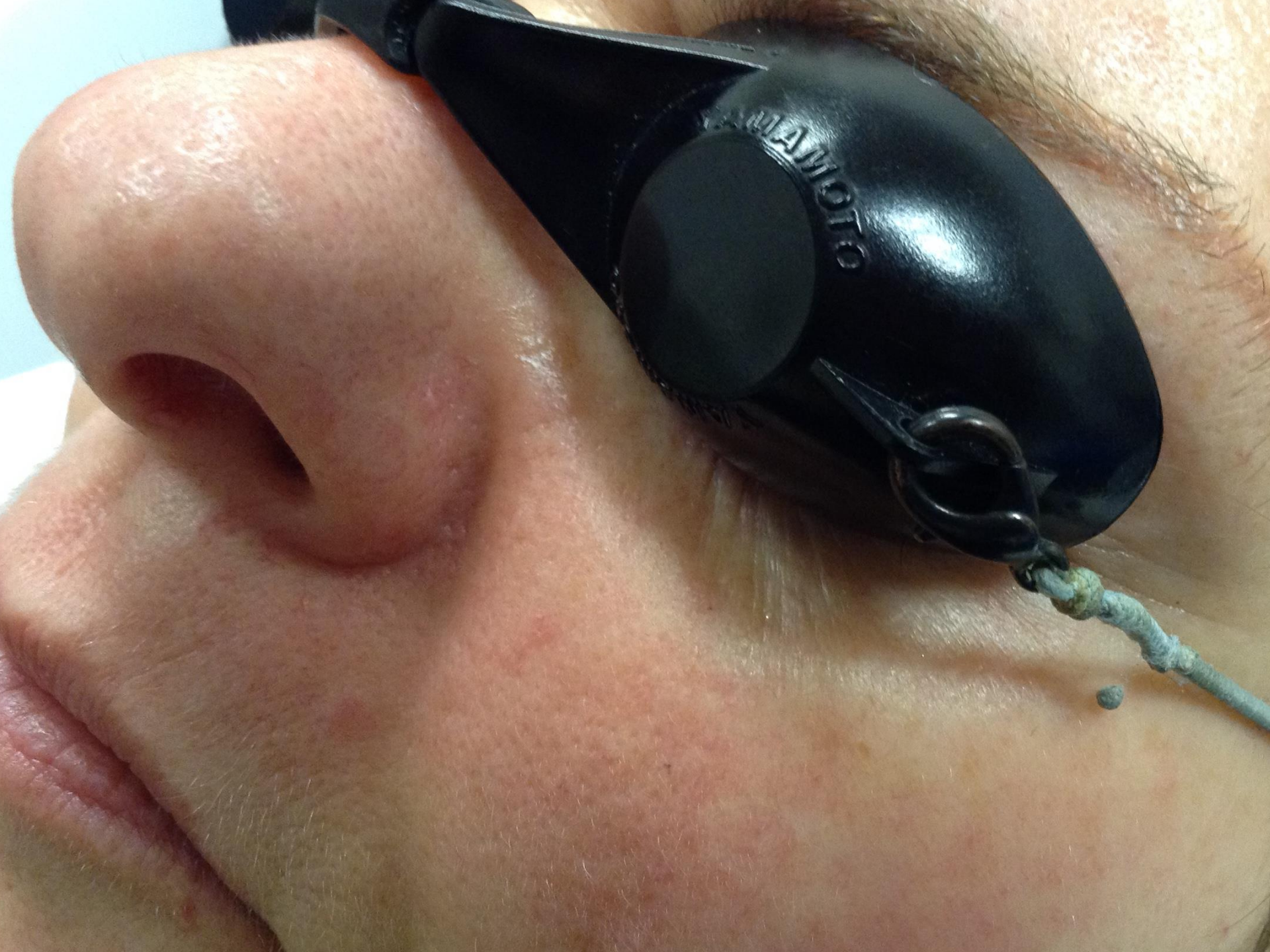


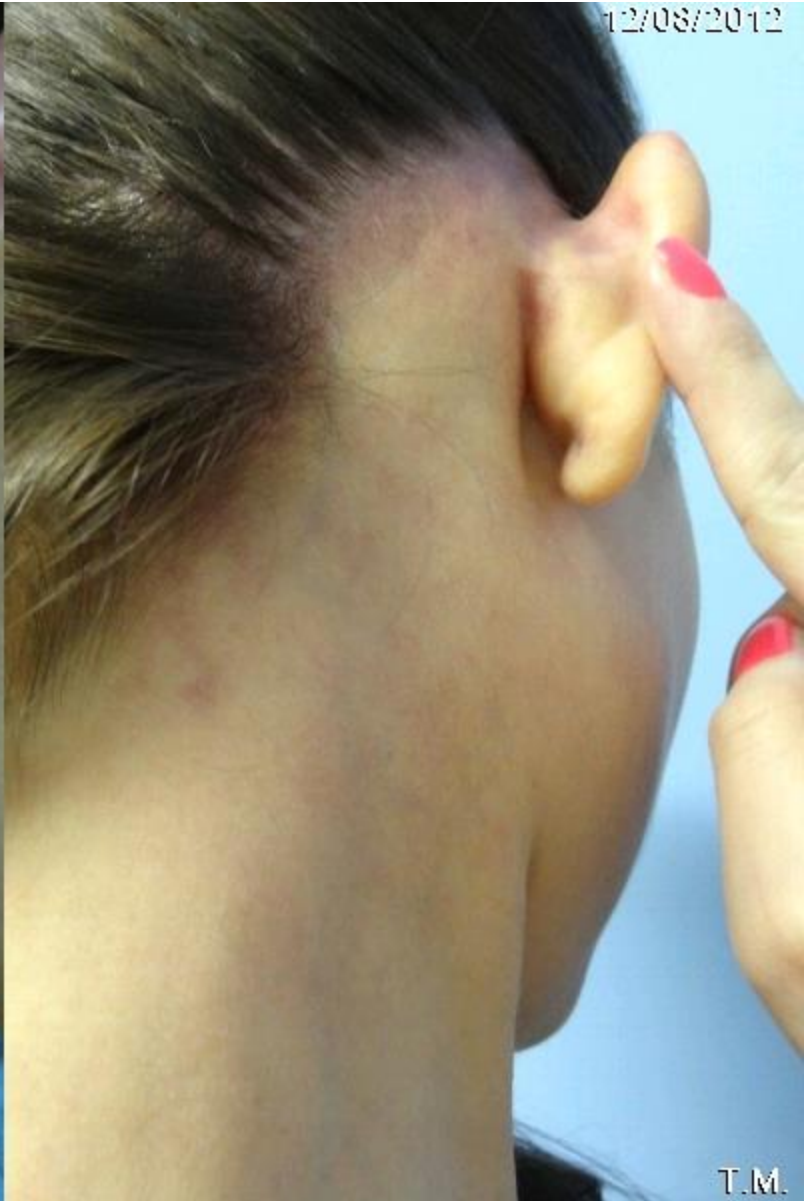
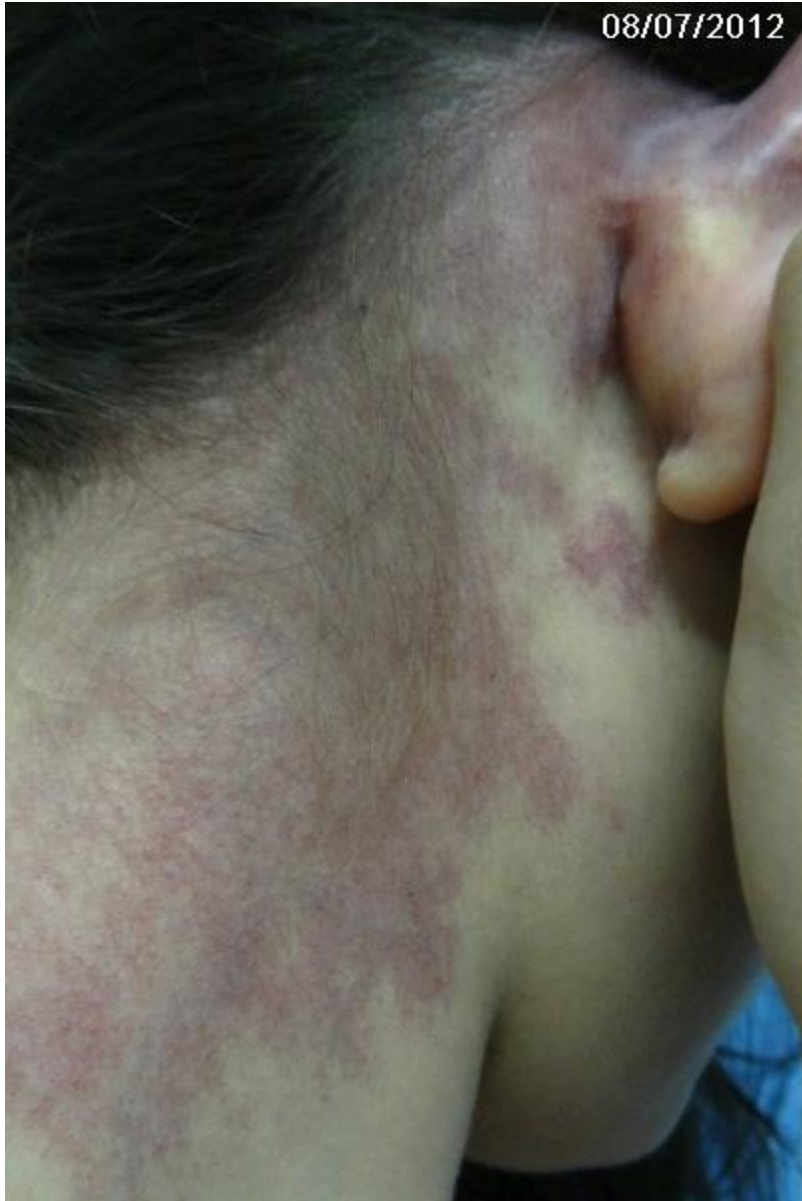


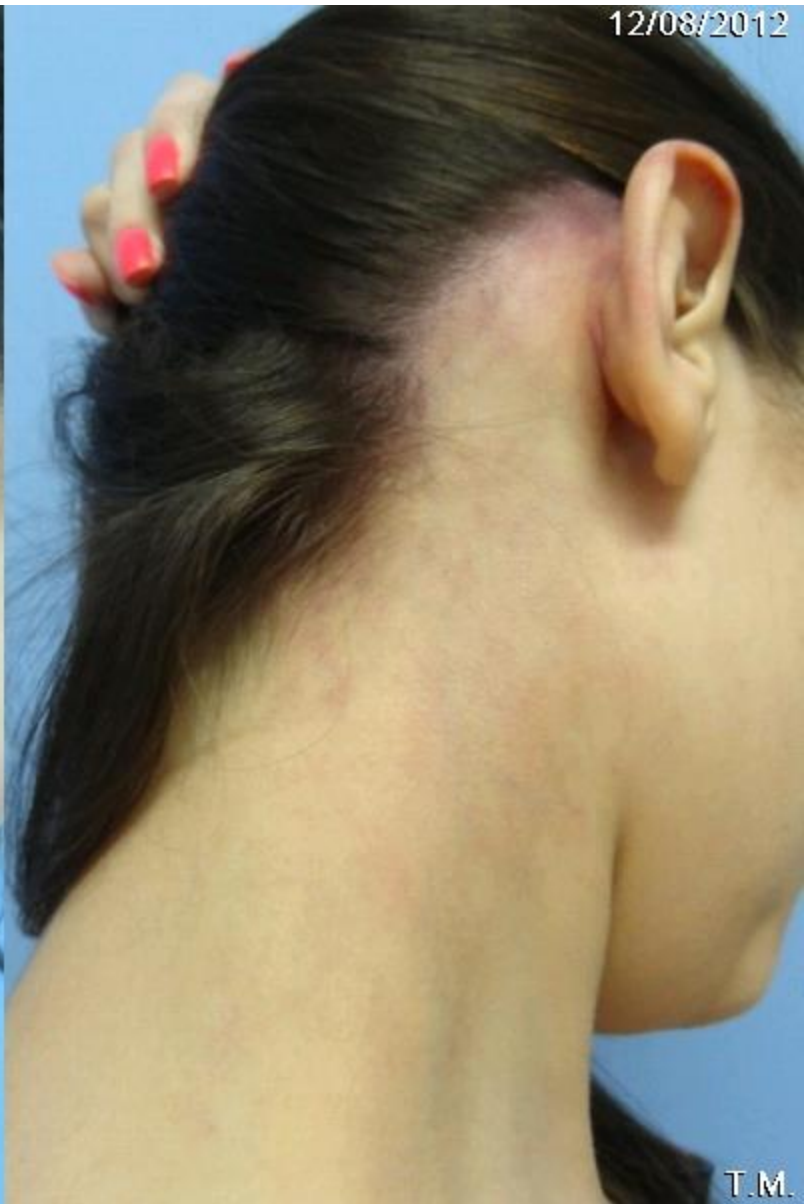
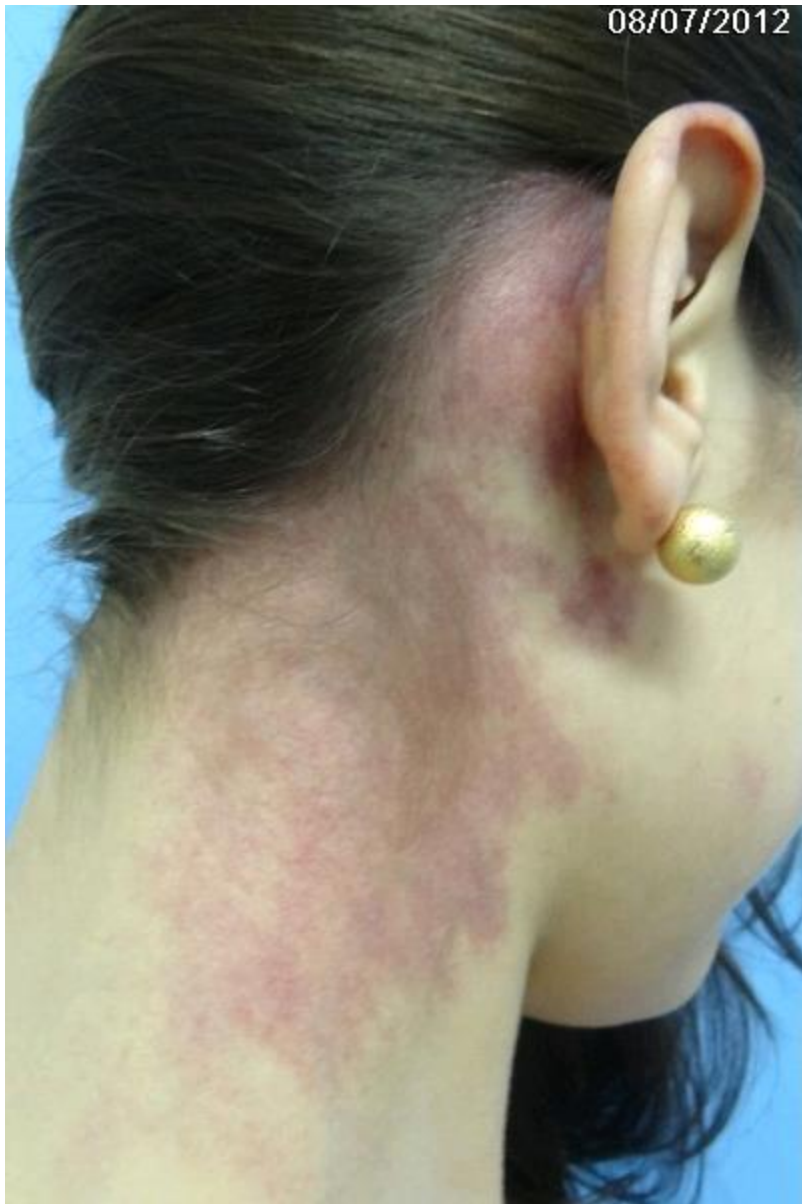




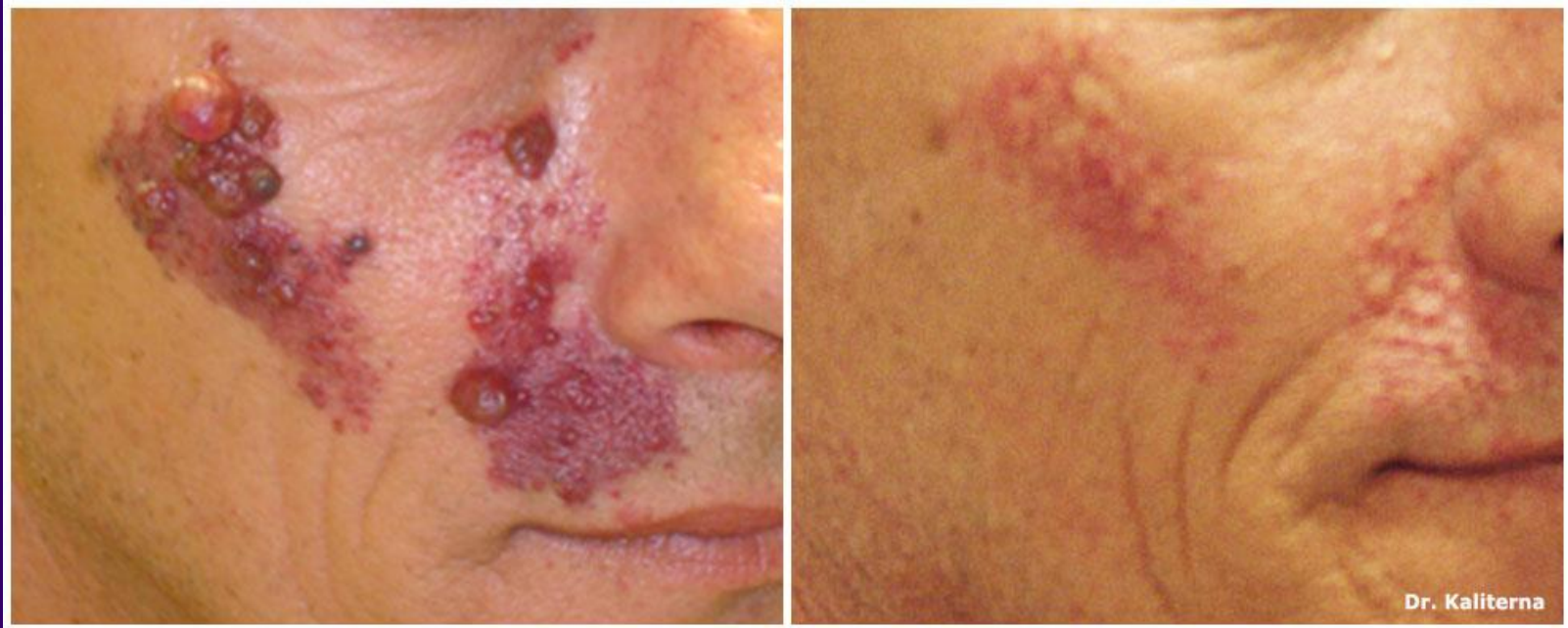T.M.

Before

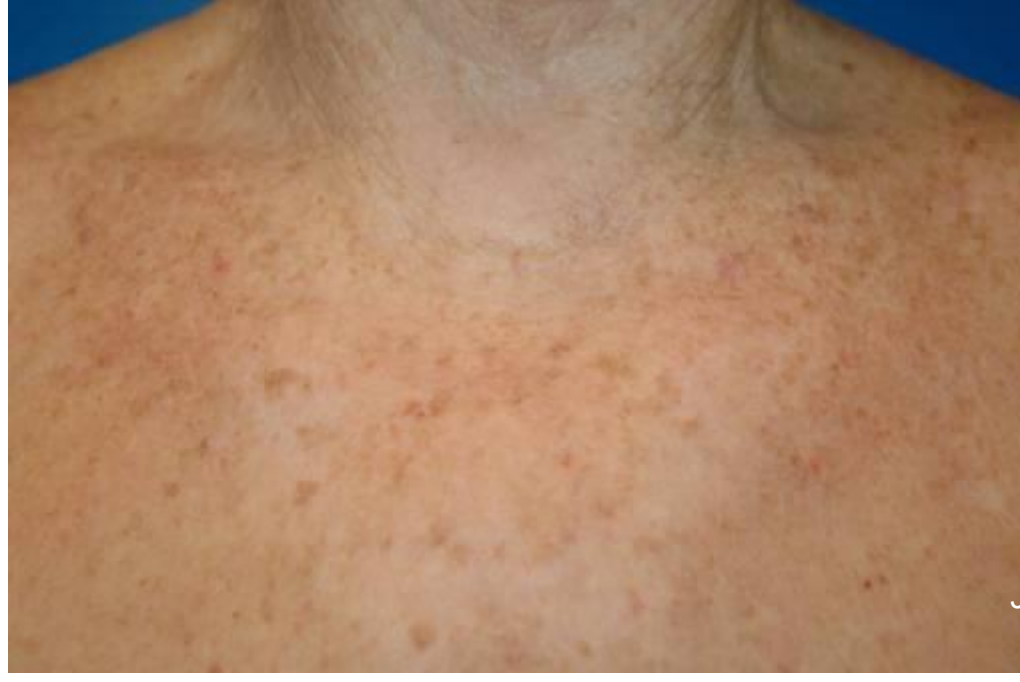After treatments



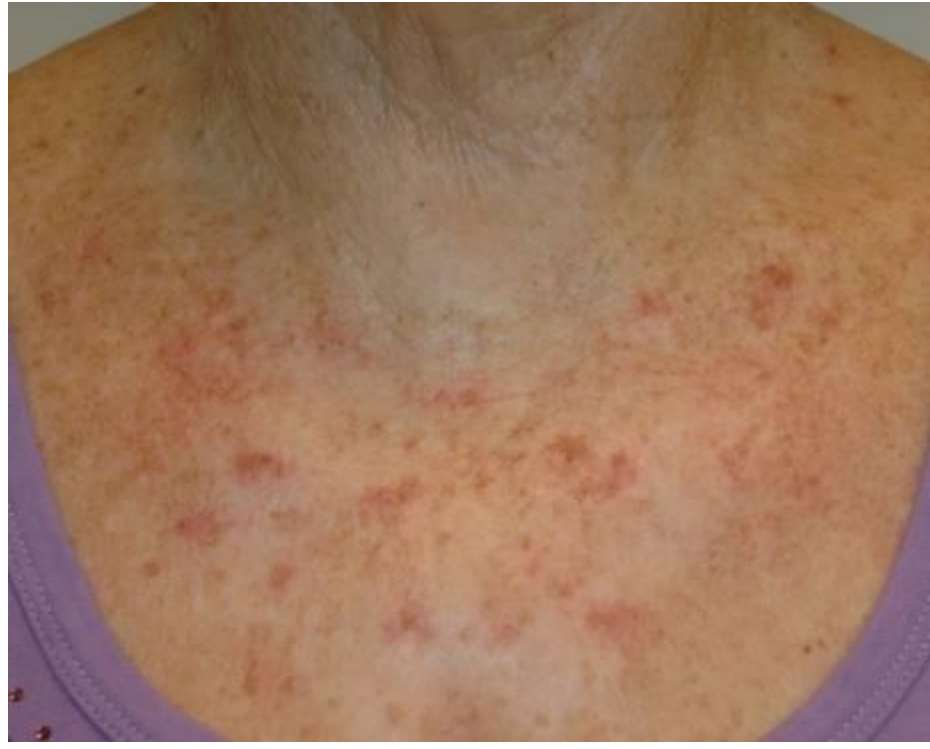Courtesy of Dr. Dinko Kaliterna, 2013

Port Wine Stain

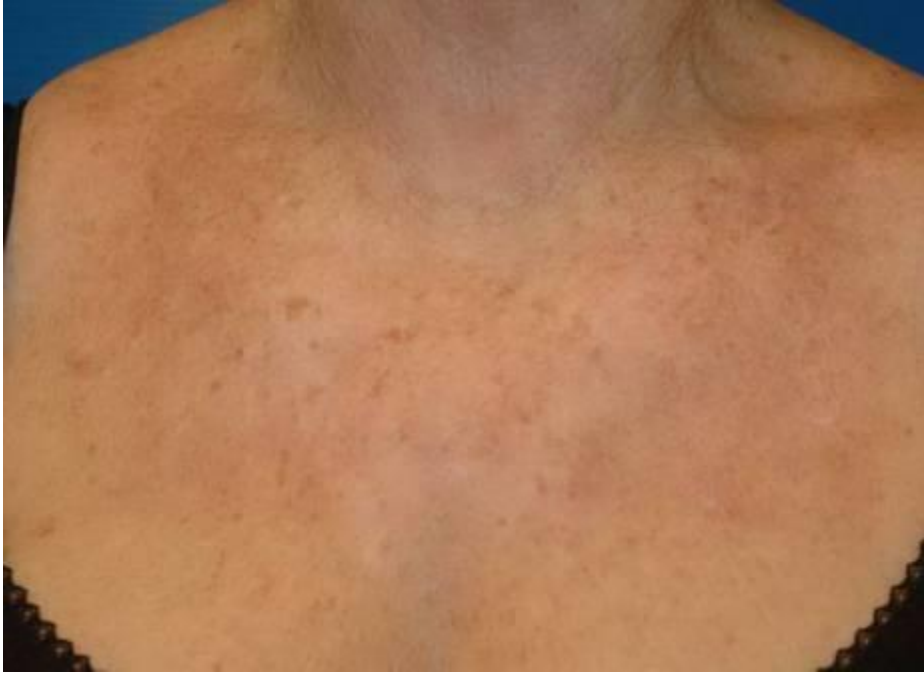3 weeks After 1 Tx



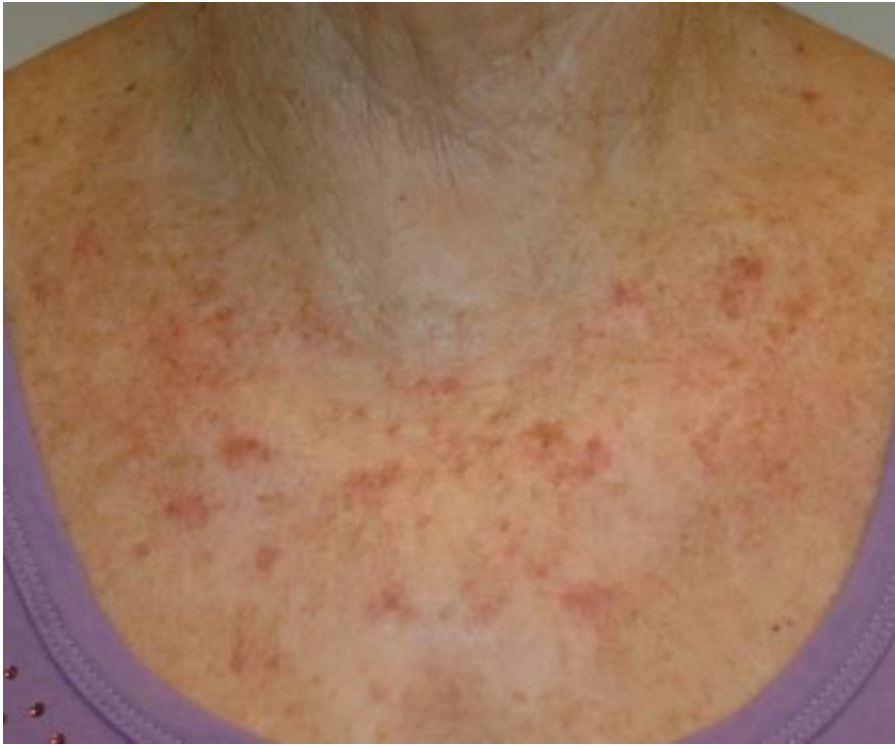Before

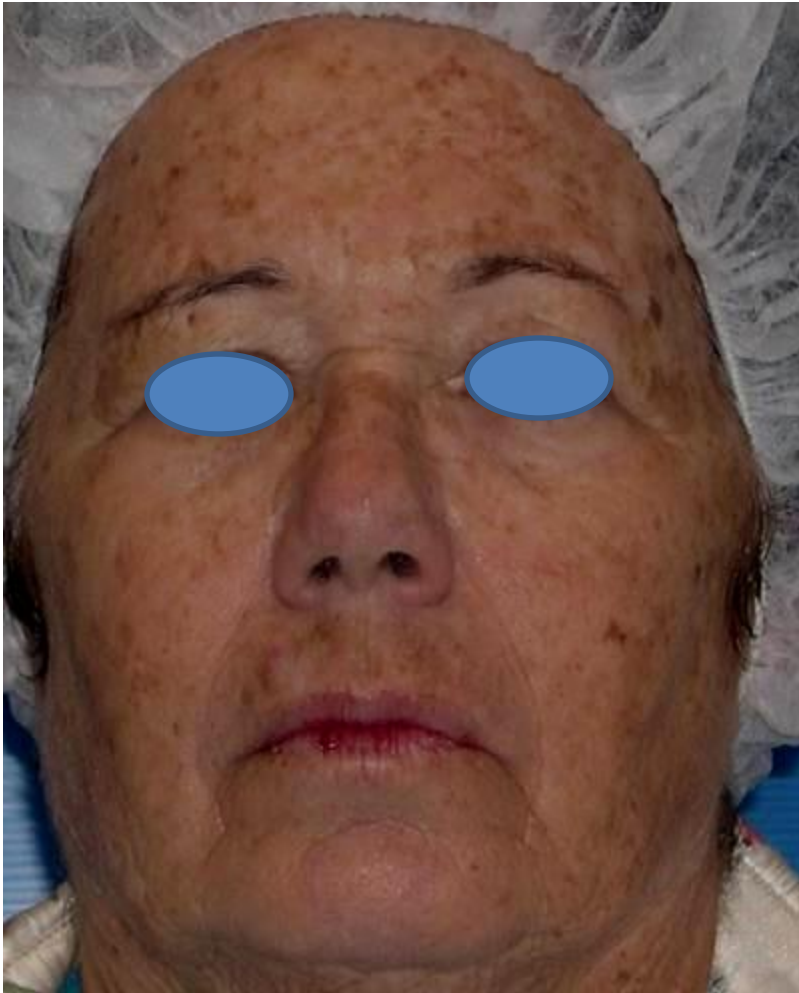

1 Month After 3 Tx

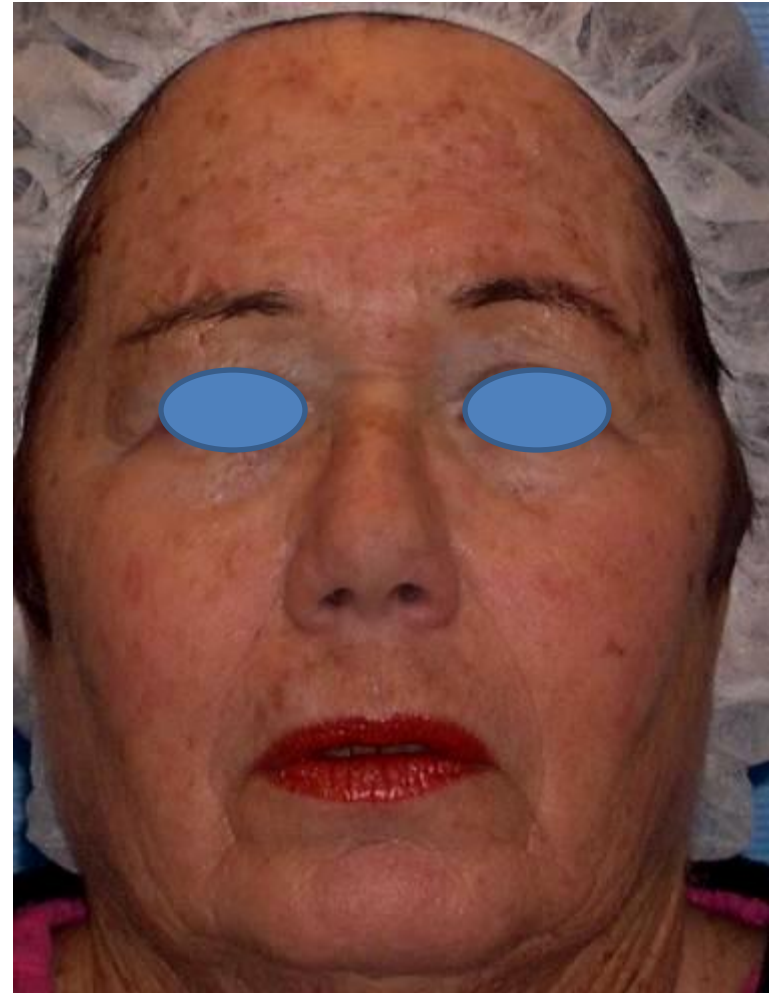

Before





Before



After 4th txt

